

CASE REPORT

Extra-adrenal Retroperitoneal Myelolipoma: A Rare Case Report

M. B. Patil¹, Manisha Victor^{1*}, Ramakanth B¹, Dayanand S. Biradar¹

¹Department of General Surgery, Bijapur Lingayat District Educational Deemed to be University's Shri B. M. Patil Medical College Hospital and Research Centre, Vijaypur-586103 (Karnataka) India

Abstract:

Myelolipoma is a rare variant of lipoma which is a benign tumor. It mimics well differentiated liposarcoma clinically and on imaging studies. Post-operative histopathological examination plays an important role in diagnosing myelolipoma. We report a case of 50 year male with rare pre-sacral retroperitoneal myelolipoma which was challenging to differentiate from liposarcoma. Following surgical resection no further treatment was needed.

Keywords: Myelolipoma, Liposarcoma, Lipoma

Introduction:

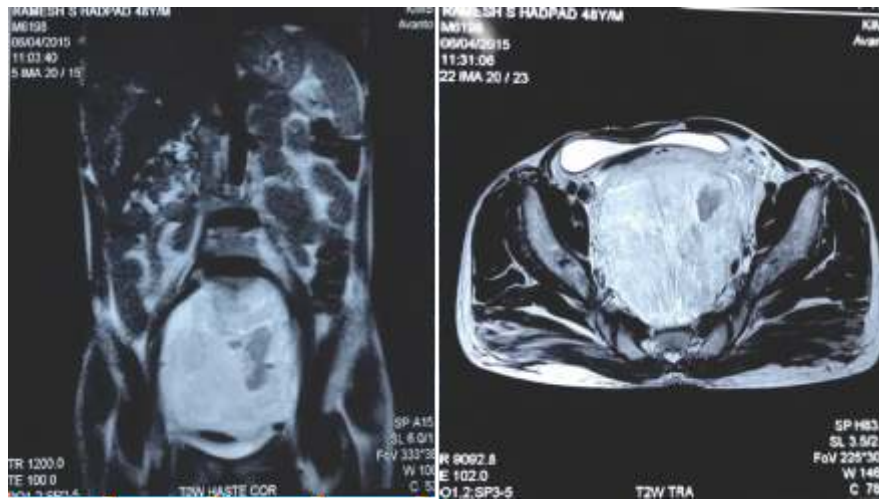Myelolipoma is a rare variant of lipoma which usually occurs in the adrenals. Extra-adrenal Myelolipomas (EAML) are most uncommon of which pre-sacral myelolipomas are the rarest. Only few more than 50 cases of EAML have been described in literature in the past two decades [1]. These are of diagnostic challenge as they are difficult to differentiate from other retroperitoneal masses such as well differentiated liposarcoma, neurogenic tumors, teratomas located in pre-sacral region [2]. Myelolipomas are benign, encapsulated tumors composed of mature adipose tissue and normal hematopoietic elements of variable proportions. These are usually non-functioning tumors which attain large size and may cause symptoms of pressure effect [1]. We report a case of 50 year old male with retroperitoneal EAML who presented to us as a well differentiated liposarcoma.

Case Report:

A 50 year old male with no apparent medical history presented to us with mass per abdomen and persistent lower abdominal pain for one year. Mass was associated with increased frequency of micturition. On examination, mass was non-tender occupying hypogastrium, umbilical region and right iliac fossa measuring around 20×14 cm. Margins were well defined. Ultrasonography of abdomen showed a large hypoechoic mass occupying the pelvis. A subsequent Magnetic Resonance Imaging (MRI) showed a large pre-sacral retroperitoneal heterogenous soft tissue mass measuring 18×13×8 cm which was displacing the rectosigmoid, colon and bladder anteriorly with areas of fat signals consistent with diagnosis of liposarcoma.

On exploratory laparotomy, two masses measuring 7×5×4 cm and 10×7×5 cm respectively were dissected from the retroperitoneum which were abutting right ureter, bladder and sigmoid colon.

On histopathological examination, tumor consisted of mature adipose tissue with hemorrhagic material, scattered megakaryocytes and myeloid series labeling the tumor as myelolipoma. Further Immunohistochemistry confirmed the diagnosis of myelolipoma. Consequently no further treatment other than surgery was indicated. There was no recurrence of the lesion during one year follow up.



Figs. 1 and 2: MRI showing a Large Retroperitoneal Mass in the Pre-Sacral Region

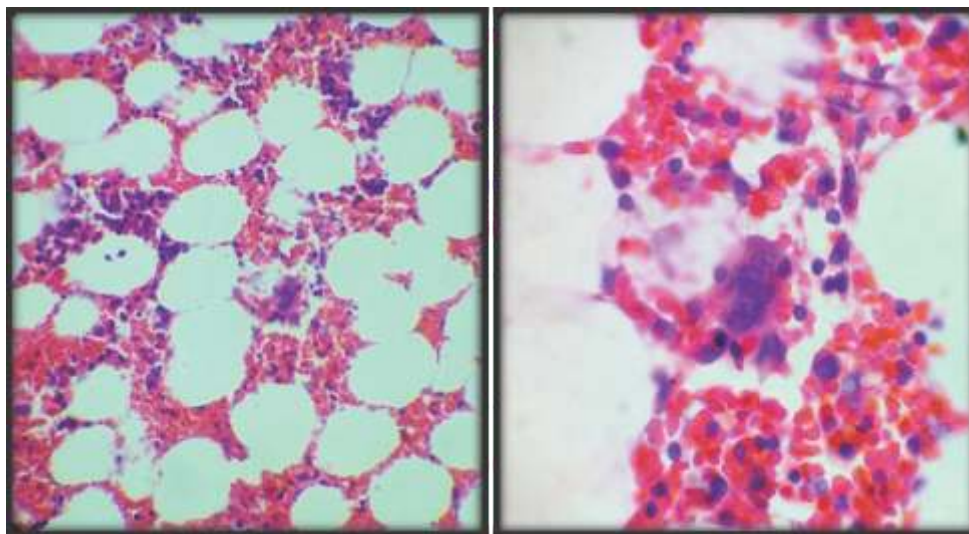
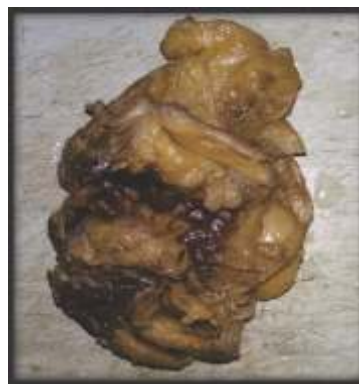

Fig. 3: H&E, 100× showing Adipose Tissue Admixed with Trilineage Hematopoietic Cells

Fig. 4: 400×High Power showing Megakaryocytes

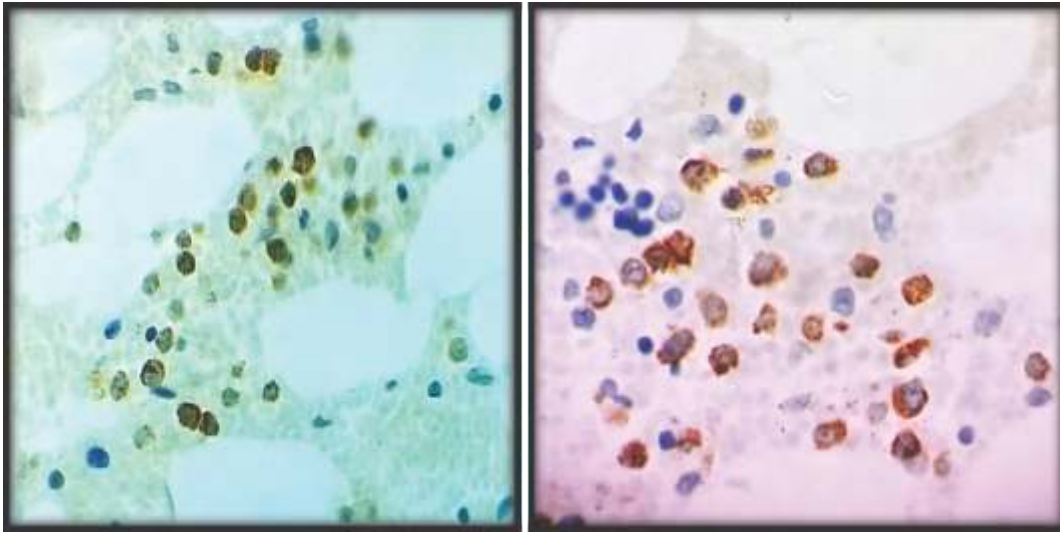


Fig. 5: Myeloperoxidase Positive for Myeloid Cells

Fig. 6: CD61 positive for Megakaryocytes showing Membrane Positivity

Discussion:

Myelolipoma is a rare benign tumor, composed of mature adipose tissue associated with variable proportion of normal hematopoietic tissue [4]. These are usually found in otherwise normal adrenals and are asymptomatic. EAML are very rare. Only 50 cases of EAML were reported in the literature [3]. Pre-sacral EAMLs are often indolent and cause no symptoms. Sometimes these can produce vague abdominal symptoms such as distension, anorexia, abdominal pain which is possibly due to tumor rupture and bleeding. The etiology of myelolipoma in general was so far unknown [1]. For EAML there are two main pathogenic hypothesis-

1. Embolization of bone marrow tissue.
2. Reactivation of peritoneal embryonic connective haematopoiesis tissue [5].

Diagnosing a retroperitoneal EAML is more difficult. A fatty retroperitoneal mass could invariably be retroperitoneal liposarcoma, renal angiolipoma, a retroperitoneal teratoma, sacrococ-

cygealchordoma, anterior sacral meningocele, presacral pelvic retroperitoneal schwannoma [4-5]. Among all, it is necessary to be able to differentiate Myelolipoma from well differentiated liposarcoma because that decides the management [4]. Histopathology plays an important role in differentiating myelolipoma from well differentiated liposarcoma. Myelolipomas as mentioned earlier are well encapsulated and are composed of variable amounts of mature adipose tissue, smooth muscle and bone marrow cells, while liposarcoma are poorly marginated, non-hemorrhagic which have lipoblast and zones of cellular atypia [1].

Conclusion:

EAML are although rare, but should be considered as a differential diagnosis for retroperitoneal mass especially liposarcoma. Biopsy is not advised due as there can be seeding of the tumor if liposarcoma is suspected. Therefore surgical resection and histopathology plays an important role in diagnosing EAML.

References

1. Zeiker D, Konigsrainer I, Miller S, Vogel U, Sotlar K, Steurer W *et al.* Simultaneous adrenal and extra-adrenal Myelolipoma- an uncommon incident: case report and review of the literature. *World J Surg Onco* 2008; 6:72.
 2. Tokuyama N, Takeuchi H, Kuroda I, Aoyagi T. Incidental Presacral Myelolipoma Resembling the Liposarcoma: A Case Report and Literature Review. *Case Rep Urol* 2016; 2016:1-5.
 3. Chauhan K, Garg M, Chaudhary M, Sharma A, Bindal T. Retroperitoneal Myelolipoma, a diagnostic dilemma: A case report and review of literature. *Saudi J Health Sci* 2016; 5(2):90-92.
 4. Butori N, Guy F, Collin F, Benet C, Causeret S, Isambert N. Retroperitoneal extra-adrenal myelolipoma: appearance in CT and MRI. *Diagn Interv Imaging* 2012; 93(3):e204-e207.
 5. Gagliardo C, Falanga G, Sutera R, La Tona G, Lo Casto A, Midiri M, *et al.* Presacral myelolipoma a case report and literature review. *Neuroradio J* 2014; 27(6):764-769.
 6. Harthi BA, Riaz MM, Khalaf AHA, Zoum MA, Shakweer WL. Adrenal Myelolipoma a rare benign tumor managed laproscopically: Report of two cases. *J Minim Access Surg* 2009; 5(4):118-120.
-

***Author for Correspondence:**

*Dr. Manisha Victor, Senior Resident. Department of General Surgery, Bijapur Lingayat District Educational Deemed to be University's Shri B. M. Patil Medical College Hospital and Research Centre, Vijaypur-586103
Email: dr.manishavic25@gmail.com Cell: 8971092315*

How to cite this article:

Patil MB, Victor M, Ramakanth B, Biradar DS. Extra-adrenal Retroperitoneal Myelolipoma: A Rare Case Report. *J Krishna Inst Med Sci Univ* 2020; 9(2): 104-107.

■ **Submitted:** 26-Jan-2020 **Accepted:** 20-Feb-2020 **Published:** 01-Apr-2020 ■