

CASE REPORT

Invasive Actinomycosis of Maxilla - An Unusual Case Report

Sunayana M. Jangla^{1*}, Bhupesh S. Machhi¹, Pallavi D. Bhandarkar²

¹Department of Pathology, Microbiology Section, ²Department of E.N.T., Bhabha Atomic Research Centre Hospital, Mumbai 400094 (Maharashtra) India

Abstract:

Cervicofacial actinomycosis is an unusual infection caused by *Actinomyces species*. It rarely involves the maxilla. We present a case of an elderly female with a left sided maxillary swelling which was diagnosed as left maxillary actinomycosis invading the adjacent structures suspected to be secondary to a bone neoplasm on the basis of histopathology. The organism grew in culture in our laboratory and hence this case is a deviation from the common feature that cultures are most of the times of little help in detecting this organism. The classical growth of this organism on culture in addition to the histopathology report highly empowered the diagnosis of this case. Also, our findings that it can permeate the surrounding structures and can produce a conundrum for the diagnosis are noteworthy.

Keywords: *Actinomyces*, Culture, Invasive, Maxilla, Maxillary Sinus

Introduction:

Actinomyces is a Gram positive, non-acid fast, thin, filamentous, anaerobic bacterium that causes actinomycosis [1]. The commonest species is *Actinomyces israeli* and cervicofacial actinomycosis is the commonest form which generally involves the cheek and submaxillary region [1]. It is endogenously present in human beings and hence infection generally occurs in patients with poor oral hygiene following trauma to the area, tooth extraction or endodontic procedure facilitating the entry of the organism into deeper tissues [1, 2].

Involvement of the maxilla is found only in 0.5-9% of all head and neck cases probably due to better blood circulation in maxilla leading to better oxygenation [3]. Invasion into the surrounding tissue is sparse. Our patient presented with extensive Actinomycosis of left sided maxilla and surrounding tissue suspected to be secondary to an osseous neoplasm as diagnosed on histopathology from an outside laboratory. Positive culture of the organism from our laboratory enhanced the diagnosis as less than half of the cases are culture positive [2, 3]. Human actinomycosis may present difficulty in diagnosing whether it is primary or secondary to an underlying lesion like a neoplasm [4], as happened in our case. We present one such remarkable case.

Case Report:

A 78 year old female presented with a lump on the left side of the upper jaw and difficulty in opening the mouth. Swelling on left side of face was noticed six months back and progressed to present size. It followed trauma to left side tooth which was self-inflicted using a wooden stick. Later, she developed ulcer in the mouth at the same site with whitish discharge. There was no history of fever. She is a case of severe aortic stenosis and calcified aortic valve with rhythm abnormality. There is no history of diabetes mellitus or other major illness. Two months after her complaints started, biopsy of

the swelling performed trans-nasally as well as trans-orally in a private institute expressed possibility of left maxillary bony tumour with acellular osteoid tissue but no conclusive report was possible. A J-needle biopsy was done, cytology performed and reported in a renowned cancer institute showed poorly differentiated tumour cells and hence repeat biopsy was advised which revealed acute osteomyelitis due to *Actinomyces* like organism secondary to an osseous neoplasm. She was treated with amoxicillin-clavulanic acid for eight days. Following this, Magnetic Resonance Imaging (MRI) was done of paranasal sinus and neck which showed left sided ulcero-proliferative growth involving hard palate, left upper alveolus with lateral extension eroding the floor and lateral wall of maxillary sinus causing fistulous communication and involvement of adjoining gingival mucosa, buccal mucosa, left high infra-temporal fossa and pterygoid muscle with effacement of left retro antral fat pad (Fig.1). On examination, the lump was situated on the left sided upper jaw and was red, circular, well-defined, laterally spreading and approximately ten centimetres in size (Fig.2). There was no discharge, fistula or granules on the outer side of the lump. Multiple discharging fistulae were seen intraorally. Pus collected from it was received for aerobic and anaerobic culture and sensitivity. Direct Gram stain showed Gram positive branching filamentous bacilli (Fig.3). Ziehl-Neelsen stain was negative. Aerobic culture grew Gram negative bacilli which were identified as *E.coli*. For anaerobic culture, pus was inoculated on Anaerobic Blood agar, Anaerobic Basal agar and Thioglycolate medium and incubated under anaerobic conditions at 37°C for 72 hours. Post enrichment, inoculation was

done from Thioglycolate medium and incubated on the same media under similar conditions. After 72 hours, there was no growth on Anaerobic Basal medium but Anaerobic Blood agar showed small, spidery colonies that became heaped up, white and irregular large colonies on further incubation showing molar-tooth appearance (Fig.4). It was identified as *Actinomyces* and the lesion was diagnosed as left maxillary actinomycosis in our institute. But species could not be identified. Anaerobic sensitivity testing was not done. She was given ampicillin-sulbactam and doxycycline for four weeks after which she was planned for left maxillectomy and infratemporal fossa clearance. Review Computerised Tomography (CT) Scan after three weeks showed no regression of the lesion. Since she was a high-risk cardiac, she refused to undergo surgery. Hence she was discharged on oral amoxicillin-clavulanic acid and doxycycline for another four weeks without any surgical intervention done.

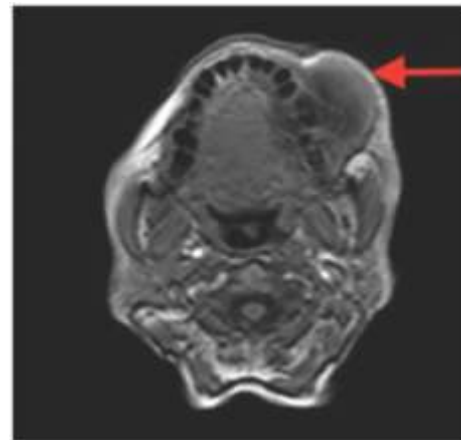


Fig. 1: Left Sided Maxillary Region Swelling Involving Maxilla and Extending Up to Upper Alveolus and Palate

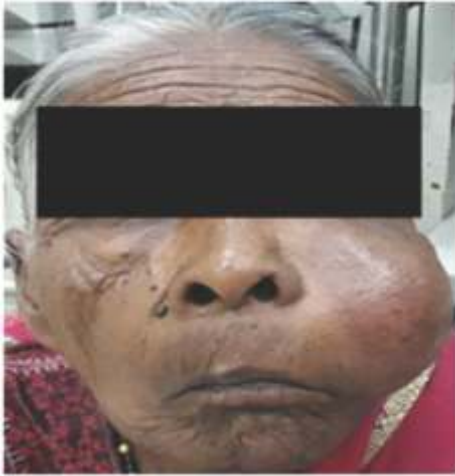

Fig. 2: Lump on Gross Examination

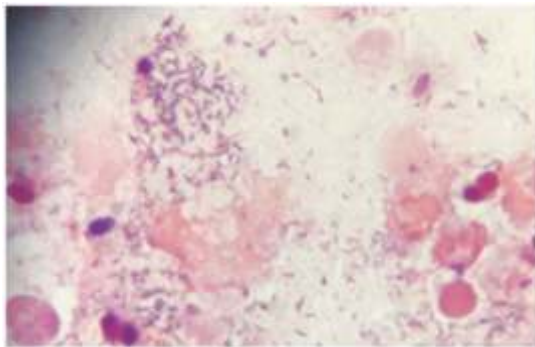


Fig. 3: Gram Stain from Pus showing Gram Positive Branching Filamentous Bacilli



Fig. 4: Molar Tooth Appearance of Colony on Anaerobic Blood Agar

Discussion:

There are few parameters which make this case interesting. Actinomycosis is a chronic granulomatous disease which is uncommon and involvement of maxilla is less common as compared to mandible with a ratio of 4:1 [5]. Also, its invasion into infratemporal fossa and maxillary

sinus are hardly reported earlier in literature. The diagnosis of actinomycosis is based particularly upon histopathology along with anatomical and radiological findings. Culture of this organism is difficult due to the incorrect handling of specimen, overgrowth of the accompanying aerobic and other anaerobic organism, inability to maintain anaerobic environment and recent antibiotic therapy [6, 7, 3]. Hence, cultures are positive in less than 50% of cases in spite of being the best modality for detecting this disease [6]. Other diagnostic modalities like Polymerase Chain Reaction (PCR) are rapid and accurate but expensive and not easily available [8, 6, 3] and was unavailable with us. However, the fact that culture was positive in our case strengthened the diagnosis though species identification was not possible. Histopathology was suggestive of a suspicious bone neoplasm in the background although it could not be confirmed by biopsy. Hence, the present lesion could be primary human actinomycosis which was mistaken for a neoplasm [9]. It could also be secondary to a neoplasm as in a case of maxillary actinomycotic osteomyelitis reported by Meethal *et al.* where the patient was known to have carcinoma breast [7]. This case was a clinical challenge as the lesion continued to increase in size with only intraoral sinuses and required multiple biopsies for diagnosis. Sulphur granules are a characteristic feature of this disease [1] but were absent in our case in multiple sinuses in the mouth. According to some authors, they are also produced by other pathogens and hence are not pathognomonic [8,5]. Hence, our case gains significance due to the site involved, invasive nature of the lesion, growth in culture, uncertainty about its nature and absence of sulphur granules. In case of large lesions, treatment is prolonged and surgical intervention along with antibiotics are required [10].

Lysis of this organism occurs at a comparatively slower rate than other microbes requiring treatment ranging from weeks to months [11, 2]. Drug of choice is penicillin and its derivatives or tetracycline given intravenously initially followed by oral route [6, 1, 2, 4]. In our case too, the patient was put on a similar regime with poor response as the bony penetration was the limiting factor. Surgical intervention was not possible due to her high-risk cardiac status and age.

Conclusion:

This case serves as a reminder that actinomycosis can rarely involve the maxilla and invade its surrounding area, posing a diagnostic dilemma. However, knowledge about the right culture techniques and its accurate application can contribute to growth of the organism and thus emancipate its detection.

References

1. Ananthnarayan R, Paniker Jayram CK. Ananthnarayan and Paniker's Textbook of Microbiology. 9 ed. Hyderabad, India: Universities Press (India) Private Limited; 2013:391-94.
2. Gaweda A, Wojciechowicz J, Barszczewski G, Tomaszewski T. Cervicofacial actinomycosis following jaw pathology-case reports. *J Pre-Clin Clin Res* 2016; 10(1):73-75.
3. Baldawa P, Shirol P, Kulkarni D, Koshti S, Mishra N. Actinomycotic osteomyelitis of palate masquerading periapical pathology: a rare case report. *Indian J Dent Res* 2018; 29:247-51.
4. Dickson-Gonzalez S, Barbella-Aponte RA, Rodriguez Morales AJ, Mota-Gamboa JD, Mata S. Actinomycosis mimicking carcinoma of the maxillary sinus: a case report. *Rev Soc Med Quir Hosp Emerg Perez de Leon* 2007; 38(2):34-65.
5. Ratnaprabhu V, Rajesh R, Sunitha M. Intraoral actinomycotic lesion: A case report. *J Indian Soc Pedod Prev Dent* 2003; 21(4):144-66.
6. Sezer B, Akdeniz GB, Gunbay S, Hilmooglu-Polat S, Basdemir G. Actinomycosis osteomyelitis of the jaws: Report of four cases and a review of the literature. *J Dent Sci* 2017; 12: 301-77.
7. Meethal C A, Pattamparambath M, Balan A, Kumar R N, Sathyabhama S. Actinomycotic osteomyelitis of the maxilla-a delusive presentation. *J Clin Diag Res* 2016; 10(7): ZJ01-ZJ03.
8. Gannepalli A, Ayinampudi KB, Baghirath VP, Reddy VG. Actinomycotic osteomyelitis of maxilla presenting as oroantral fistula: a rare case report. *Case Rep Dent* 2015; 2015: 689240.
9. Batur Calis A, Ozbal AE, Basak T, Turgut S. Laryngeal actinomycosis accompanying laryngeal carcinoma: Report of two cases. *Eur Arch Otorhinolaryngol* 2006; 263(8):783-5.
10. Klein M, Carrad CV, Munerato CM. Cervicofacial actinomycosis of the maxilla and HIV infection: a case report. *Otolaryngol (Sunnyvale)* 2017; 7:1.1000288.
11. Perumal C J, Singh A S, Rajkumar K. Chronic suppurative osteomyelitis of the maxilla and zygomatic bone: a treatment challenge and the importance of early surgical exploration. *S Afr Dent J* 2016; 71(9):412-14.

*Author for Correspondence: Dr Sunayana M. Jangla, Microbiology Section, Department of Pathology, Bhabha Atomic Research Hospital, Trombay, Mumbai 400-094, Maharashtra
Email:sunayanajangla79@gmail.com Cell: 9819039287