
ORIGINAL ARTICLE**An analytical observational trichoscopic study of common scalp disorders with alopecia with a simplified diagnostic algorithm**

Pol Devayani¹, Shinde Rajendra¹, Kumar Ajay^{1*}, Gaikwad Rohini¹, Priya Garg¹, Deoghare Shreya¹

¹Department of Dermatology, Venereology and Leprosy, Dr. D. Y. Patil Medical College, Hospital and Research centre, Pimpri, Pune- 411018 (Maharashtra) India

Abstract

Background: Dermoscopy is a non-invasive method of evaluating disorders of the skin. Dermoscopy of hair and scalp disorders termed trichoscopy is useful in assessing scalp disorders with alopecia. **Aim and Objectives:** The aim of the study was to evaluate trichoscopic features of common scalp disorders with alopecia. The primary objective was to identify distinctive features of these disorders while the secondary objective was to formulate a simplified algorithm to arrive at a diagnosis. **Material and Methods:** A descriptive, cross sectional study of common scalp disorders with alopecia was conducted over a period of 2 years at a tertiary care centre. Two hundred cases were enrolled after obtaining approval of ethics committee and informed consent of patients. A detailed history was taken and general physical and dermatological examination carried out. Trichoscopic evaluation was carried out using Heine Delta 20T dermatoscope. **Results:** Common scalp disorders with alopecia included male pattern androgenetic alopecia (20.5%), alopecia areata (19.5%), telogen effluvium (12.5%) and female pattern hair loss (10.5%) and their trichoscopic features were tabulated. On the basis of trichoscopic features, an algorithm for rapid diagnosis was formulated. **Conclusion:** Common scalp disorders with alopecia have characteristic trichoscopic signs. A simplified algorithm formulated from the study may help in rapid diagnosis.

Keywords: Scalp disorder, alopecia, trichoscopy, algorithm

Introduction

Dermoscopy is a non-invasive imaging technique to visualise structures in the epidermis, dermoepidermal junction and papillary dermis. Friedman *et al.*, in 1991 used the term for epiluminescence microscopy to evaluate malignant melanoma [1]. Rudnicka and Olszewska termed dermoscopy of hair and scalp disorders as trichoscopy at a conference in Warsaw, Poland in 2006 [2]. Scalp disorders with hair loss may be cicatricial or non cicatricial. Subtle signs of cicatricial alopecia that are not evident clinically are readily discernible on trichoscopy [3]. In cicatricial alopecia trichoscopic signs of disease activity such as peripilar casts in lichen planopilaris and discoid lupus erythematosus

are useful in selecting the site for skin biopsy [4].

The diagnosis of scalp disorders with alopecia is often challenging and confirmation is sought through histopathology. This approach may be difficult or unacceptable to patients. In recent years the non-invasive technique of trichoscopy has been used to visualize submacroscopic structures in order to arrive at a diagnosis. The aim was to evaluate the trichoscopic features of common scalp disorders with alopecia. The primary objective was to compare the trichoscopic signs of common alopeic disorders. The secondary objective was to formulate an uncomplicated algorithm to arrive at the diagnosis.

Materialand Methods

This descriptive cross-sectional study was carried out over a period of two years in a tertiary care centre to evaluate the role of dermoscopy in the diagnosis of scalp disorders with alopecia. Two hundred patients of either sex, aged 10 years or above attending dermatology outpatient department were included in the study. Sample size was estimated using the survey system. With a confidence level of 95% and confidence interval of 7, the sample size was estimated to be 196 using the survey system. Hence a sample size of 200 was considered adequate for our study. Approval of the institutional ethics committee and written informed consent of patients or guardians was obtained in all

cases. Sample characteristics were noted and a detailed history was taken. A complete general physical, systemic and dermatological examination was carried out. Trichoscopic findings using Heine Delta 20T Dermatoscope were recorded. Statistical analysis whenever required was carried out using MS Excel and SPSS version 20.0 software.

Results

Common scalp disorders with alopecia included male pattern androgenetic alopecia (20.5%), alopecia areata (19.5%), telogen effluvium (12.5%) and female pattern hair loss (10.5%) in the present study and their trichoscopic findings were tabulated (Table 1).

Table 1: Trichoscopic findings of various scalp disorders with alopecia

Hair and scalp disorders	Number (%)	Trichoscopic findings	Number (%)
Male pattern androgenetic alopecia (MAGA)	41 (20.5)	Diameter diversity >20% due to hair miniaturisation Yellow dots Thin hair Vellus hair Honeycomb pigment network Peripilar sign	41 (100) 39 (95.1) 37 (90.2) 17 (41.5) 15 (36.6) 4 (9.8)
Alopecia areata	39 (19.5)	Black dots Yellow dots Exclamation mark hair Vellus hair Pigtail regrowing hairs Tulip hair	32 (82.1) 29 (74.4) 27 (69.2) 20 (51.3) 15 (38.5) 2 (5.1)
Telogen effluvium	25 (12.5)	Reduced hair density Yellow dots Short tip regrowing hair Peripilar erythema	18 (72) 12 (48) 3 (12) 1 (4)
Female pattern androgenetic alopecia (FAGA)	21 (10.5)	Diameter diversity >20% due to hair miniaturisation Yellow dots Vellus hair Honeycomb pigment network Peripilar sign	18 (85.7) 10 (47.6) 6 (28.6) 3 (14.3) 3 (14.3)

Continued...

Hair and scalp disorders	Number (%)	Trichoscopic findings	Number (%)
Tineacapitis	15 (7.5)	Comma hair Corkscrew hair Zigzag hair Morse code hair Black dots	11 (73.3) 10 (66.7) 8 (53.3) 4 (26.6) 2 (13.3)
Lichen planopilaris (LPP)	13 (6.5%)	Loss of follicles Structureless white areas Honeycomb pigment network Blue gray dots (perifollicular) White dots Peripilar scaling Peripilar erythema Peripilar casts Cadaverized hair	13 (100) 11 (84.6) 9 (69.2) 7 (53.8) 6 (46.2) 5 (38.5) 2 (15.4) 1(7.7) 1(7.7)
Seborrheic dermatitis	13 (6.5)	Arborizing vessels Yellow perifollicular scaling	13 (100) 10 (76.9)
Scalp psoriasis	11 (5.5)	White scaling Twisted red loops Red dots and globules Glomerular loops	11 (100) 11 (76.9) 8 (72.7) 5 (45.4)
Discoid lupus erythematosus (DLE)	10 (5)	Loss of follicular openings Structureless white areas Arborizing vessels Perifollicular erythema Blue-grey dots (peri + interfollicular) Follicular plugs Honeycomb pigmentation Perifollicular scaling Tubular scaling Circular hair	9 (90) 8 (80) 6 (60) 5 (50) 5 (50) 4 (40) 3 (30) 2 (20) 1 (10) 1 (10)
Trichotillomania	7 (3.5)	Uneven broken hair Black dots Split ends Tulip hair V sign Follicular hemorrhage Honeycomb pigment network	7 (100) 6 (85.7) 6(85.7) 5 (71.4) 5 (71.4) 4 (57.1) 1 (14.3)
Pediculosiscapitis	2 (1)	Nits	2 (100)
Morphea	1 (0.5)	White areas	1 (100)
Trichorrhesisnodosa	1 (0.5)	Acute angulation of hairs	1 (100)
Nevus sebaceous	1 (0.5)	Comedo like openings	1(100)
Total	200 (100)		

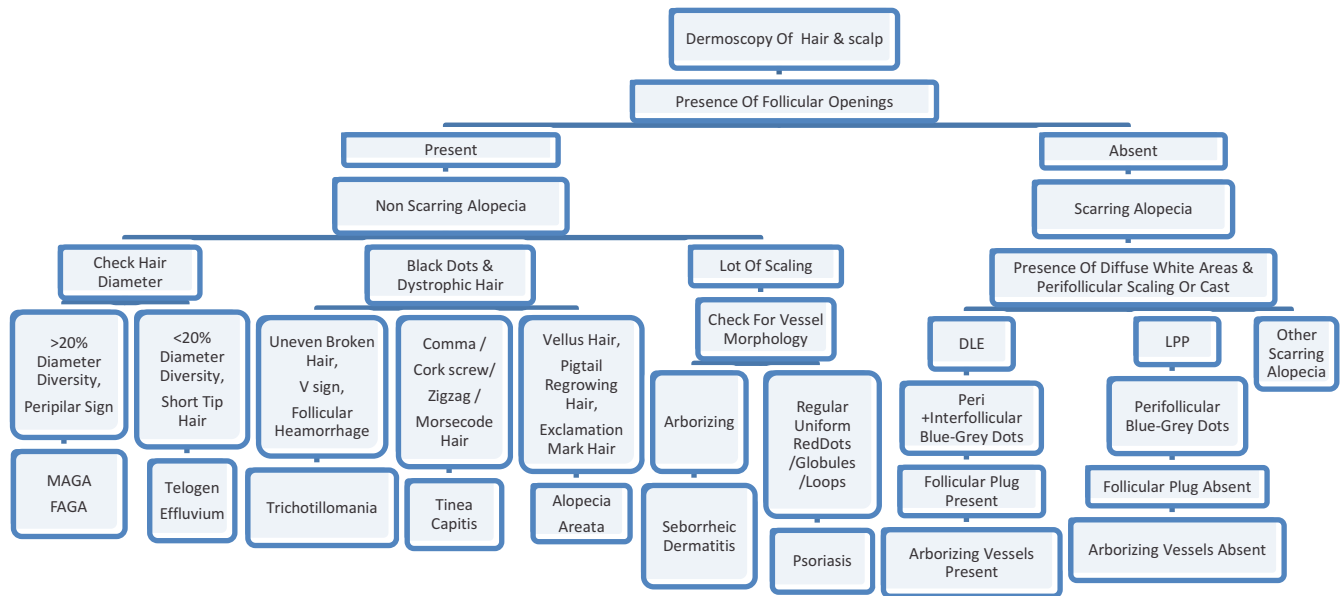


Figure 1: A simplified diagnostic algorithm for common scalp disorders with alopecia

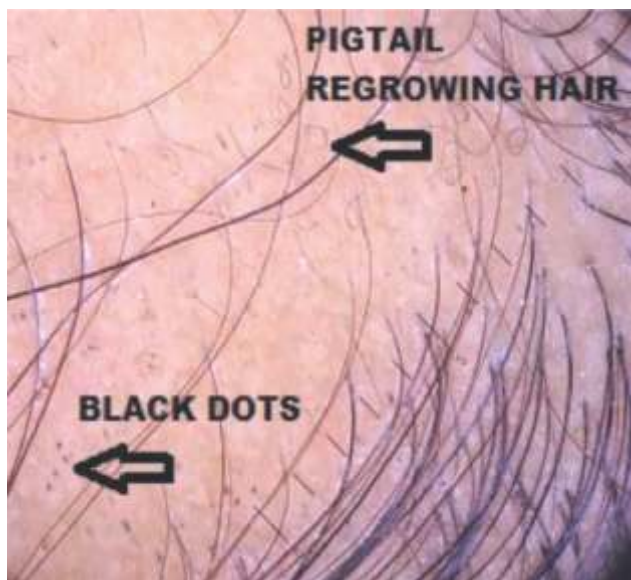


Figure 2: Regrowing hair bend back upon themselves as pigtail or circle hair in alopecia areata. Black dots are also seen in the image

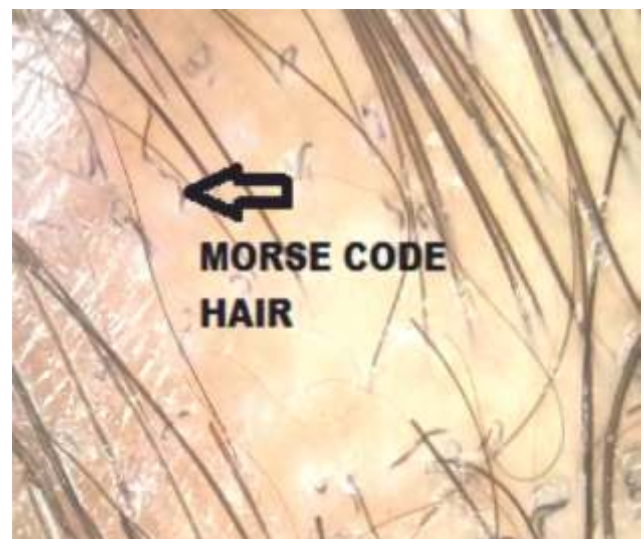

Figure 3: Morsecode hair with thin white bands due to perforation of hair shaft in ectothrix type infection

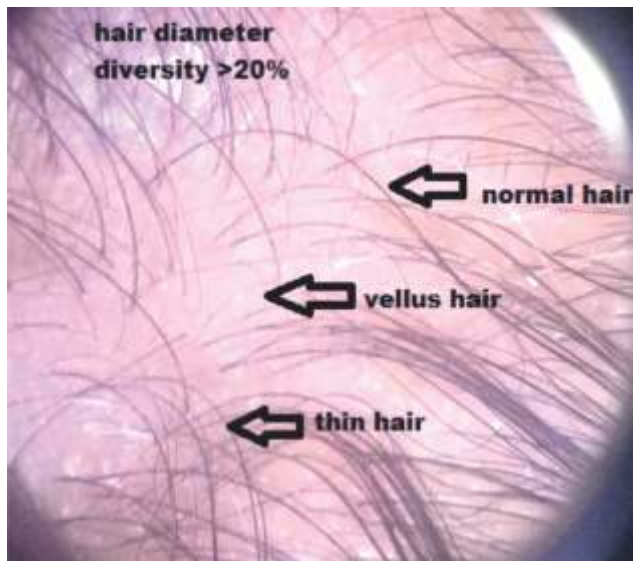

Figure 4: Diameter diversity >20% due to hair miniaturisation in androgenetic alopecia

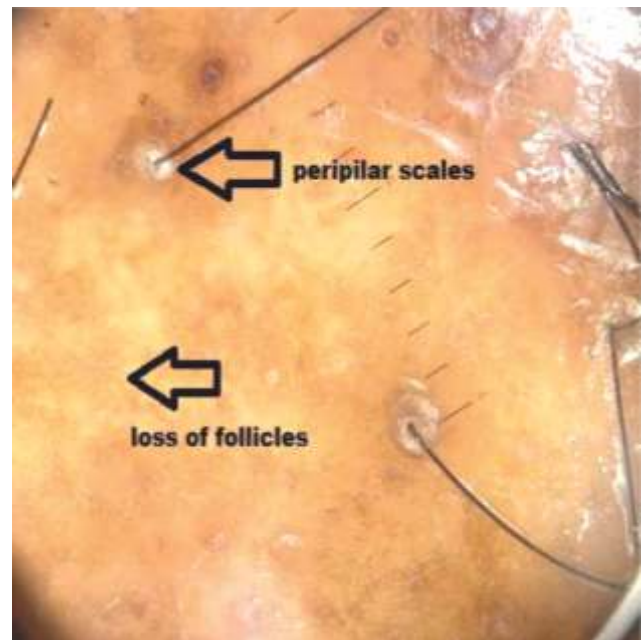


Figure 5: Loss of follicles and peripilar scales in lichen planopilaris

Discussion

Anisotrichosis or variation in hair shaft diameter on trichoscopy is a specific diagnostic feature that was noted in all cases of male and female androgenetic alopecia in our study [5-6]. The presence of round or polycyclic yellow dots on trichoscopy due to persistent sebaceous glands with follicular atrichia is not a specific sign of androgenetic alopecia as it is also observed in alopecia areata, congenital hypotrichosis and trichotillomania [5-7]. In the present study yellow dots were more common in male (95.1%) than female (47.6%) androgenetic alopecia cases. The peripilar trichoscopic sign, specific for androgenetic alopecia, is a brown perifollicular halo due to inflammation in early stages and was reported in 31.6% and 40.38% of cases in previous studies carried out in Egypt and Bosnia respectively [5-6]. Our study is at variance with the above studies and the peripilar sign was

noted in only 9.8% male and 14.3% female androgenetic alopecia cases. Honeycomb pigmentation pattern due to chronic sun exposure is a grid of irregular lines consistent with melanin in rete ridges and hypomelanotic holes representing suprapapillary epidermis which is not specific for androgenetic alopecia as it is also observed in actinically damaged skin and in discoid lupus erythematosus [8]. In the present study honeycomb pigmentation was more common in male (36.6%) than female (14.3%) androgenetic alopecia cases. Black dots on trichoscopy represent dystrophic hair broken off at the infundibular opening and are characteristic of alopecia areata but are also observed in conditions such as trichotillomania [9]. Black dots were observed in 82.1% of cases of alopecia areata in our study. Yellow dots representing infundibula filled with sebum and keratin are

sensitive but not specific diagnostic markers of alopecia areata [10] and were observed in 74.4% of cases in the present study. Exclamation mark hair, characterised by thin proximal and thicker distal ends, the pathognomic trichoscopic sign of alopecia areata is also observed in trichotillomania and anagen effluvium [10]. In our study exclamation mark hair were noted in 69.2% of cases of alopecia areata. Regrowing hair bend back upon themselves as pigtail or circle hair and these were observed in 38.5% of cases of alopecia areata in the present study [9].

Telogen effluvium is a diagnosis of exclusion and may be suspected by trichoscopic evidence of empty follicles and short regrowing hair without hair diameter diversity [3, 11]. Hair density was reduced in 72%, yellow dots indicating empty follicles filled with keratin and sebum were observed in 48% and short tip regrowing hair in 12% of cases of telogen effluvium in our study.

Change in shape and architecture of hair shaft due to direct invasion by dermatophytes results in comma, zigzag and corkscrew hair [9] which were observed in 73.3%, 53.3% and 66.7% of cases of tineacapitis respectively, which is common in paediatric age group [12]. Morse code like hair with thin white bands due to perforation of hair shaft in ectothrix type infection were observed in 26.6% cases in our study [13].

Invasion with breakage of hair shaft in the opening of the infundibulum resulting in black dots [9] were observed in 13.3.% of cases in the present study.

The trichoscopic features of lichen planopilaris include perifollicular inflammation with erythema resulting in perifollicular scaling and peripilar casts, blue-grey dots due to pigment incontinence,

replacement of scarred follicles by fibrous tracts leaving white dots and structureless white areas and honeycomb pigmentation pattern in the interfollicular region [11, 14]. In the present study loss of hair follicles due to scarring was observed in all cases of lichen planopilaris while structureless white areas, white dots, blue-gray dots, perifollicular erythema, perifollicular scaling, peripilar casts and honeycomb pigmentation were noted in 84.6%, 46.2%, 53.8%, 15.4%, 38.5%, 7.7% and 53.8% of cases respectively.

The trichoscopic features of seborrhoeic dermatitis include thin arborising vessels, atypical vessels, twisted red loops, glomerular vessels and perifollicular scaling [14]. In our study arborising vessels were observed in all cases while yellow perifollicular scaling was noted in 76.9% of cases of seborrhoeic dermatitis.

In scalp psoriasis, dilated tortuous vessels in the papillary dermis are visualised on trichoscopy as red dots and globules in areas with suprapapillary thinning, twisted red loops in areas with suprapapillary acanthosis and as glomerular loops in areas with more preserved thickness [9]. In our study we observed red dots and globules in 72.7%, twisted red loops in 76.9% and glomerular loops in 45.4% of cases. White perifollicular scaling was observed in all cases in our study.

The most common trichoscopic findings in patients with discoid lupus erythematosus on the scalp in our study were loss of follicular openings (90%), structureless white areas (80%), arborizing vessels (60%), perifollicular erythema (50%), blue-grey dots (50%) and follicular plugs (40%). Other findings were honeycomb pigment pattern (30%), perifollicular scaling (20%), tubular scaling (10%) and pili torti (10%).

In scalp discoid erythematosus, loss of follicular openings as well as structureless white areas are consistent with cicatricial alopecia, arborizing vessels constitute the commonest vascular pattern and blue-grey dots indicate pigment incontinence [15]. The uncommon 'red spider on a yellow dot' sign indicating an empty follicle with overlying arborizing vessels was not observed in the present study [9, 15].

The trichoscopic features of trichotillomania include uneven broken hair of different lengths, irregular black dots of variable shape and size, short broken off hair curling back either as coiled or as hook hair, broken off hair with dark leaf like distal ends called tulip hair, with Y-shaped distal ends called split ends and two broken hair of same length emerging from the same follicle called V-sign [9]. In our study uneven broken hair were

observed in all cases while irregular black dots, split ends, tulip hair and V-sign were observed in 85.7%, 85.7%, 71.4% and 71.4% of cases of trichotillomania respectively.

The limitations of our study are that histopathological confirmation of the diagnosis was carried out in very few cases. The algorithm is not comprehensive and includes only common alopecic scalp disorders.

Conclusion

Despite the availability of comprehensive texts on trichoscopic features there is a lacuna in the availability of flowcharts to facilitate an accurate diagnosis. In our study we have analysed trichoscopic features of common disorders of the scalp with alopecia and devised a simplified diagnostic algorithm.

References

1. Friedman RJ, Rigel DS, Silverman MK, Kopf AW, Vossaert KA. Malignant melanoma in the 1990s: the continued importance of early detection and the role of physician examination and self-examination of the skin. *CA Cancer J Clin* 1991; 41(4):201-26.
2. Rudnicka L, Olszewska M, Majsterek M, Czuwara J, Slowinska M. Presence and future of dermoscopy, *Expert Rev Dermatol* 2006; 1(6): 769-772.
3. Miteva M, Tosti A. Hair and scalp dermatoscopy. *J Am Acad Dermatol* 2012; 67(5): 1040-1048.
4. Miteva M, Tosti A. Dermoscopy guided scalp biopsy in cicatricial alopecia. *J Eur Acad Dermatol Venereol* 2013; 27(10):1299-303.
5. Kasumagic-Halilovic E. Trichoscopic findings in androgenetic alopecia. *Med Arch* 2021; 75(2):109-111.
6. Tawfik SS, Sorour OA, Alariny AF, Elmorsy EH, Moneib H. White and yellow dots as new trichoscopic signs of severe female androgenetic alopecia in dark skin phototypes. *Int J Dermatol* 2018; 57(10):1221-1228.
7. Rudnicka L, Rakowska A, Kerzeja M, Olszewska. Hairshafts in trichoscopy: clues for diagnosis of hair and scalp diseases. *Dermatol Clin* 2013; 31(4):695-708.
8. Ross EK, Vincenzi C, Tosti A. Videodermoscopy in the evaluation of hair and scalp disorders. *J Am Acad Dermatol* 2006; 55(5):799-806.
9. Fernandez-Flores A, Cabo F. [Translated article] histopathologic and trichoscopic correlations in nonscarring alopecias. *Actas Dermosifiliogr* 2023; 114(6):T502-T511.
10. Waśkiel A, Rakowska A, Sikora M, Olszewska M, Rudnicka L. Trichoscopy of alopecia areata: An update. *J Dermatol* 2018; 45(6):692-700.
11. Jain N, Doshi B, Khopkar U. Trichoscopy in alopecias: diagnosis simplified. *Int J Trichology* 2013; 5(4):170-8.
12. Kothari RS, Raheja A, Rakesh A, Deora MS, Patil A, Deoghare S. Study of patterns of dermatoses in paediatric attendees of a tertiary care hospital at Pune. *J Krishna Inst Med Sci Univ* 2021; 10(4):74-791.

-
13. Waśkiel-Burnat A, Rakowska A, Sikora M, Ciechanowicz P, Olszewska M, Rudnicka L. Trichoscopy of Tinea Capitis: A Systematic Review. *Dermatol Ther (Heidelb)* 2020; 10(1):43-52.
 14. Golińska J, Sar-Pomian M, Rudnicka L. Diagnostic accuracy of trichoscopy in inflammatory scalp diseases: a systematic review. *Dermatology* 2022; 238(3):412-421.
 15. Żychowska M, Żychowska M. Dermoscopy of discoid lupus erythematosus - a systematic review of the literature. *Int J Dermatol* 2021; 60(7):818-828.
-

***Author for Correspondence:**

Dr. Ajay Kumar, U-1/7 AWHO Tucker Enclave,
Hadapsar, Pune-411028, Maharashtra
Email: ajaikmathur@gmail.com
Phone: 020 9468085015

How to cite this article:

Pol D, Shinde R, Kumar A, Gaikwad R, Garg P, Deoghare S. An analytical observational trichoscopic study of common scalp disorders with alopecia with a simplified diagnostic algorithm. *J Krishna Inst Med Sci Univ* 2024; 13(1):78-85.

■ **Submitted:** 10-Oct-2023 **Accepted:** 10-Dec-2023 **Published:** 01-Jan-2024 ■
