
CASE REPORT**A rare case of Poland's syndrome with contralateral gynaecomastia: A case report***Gupta Saurabh^{1*}**¹Department of Surgery, Adesh Institute of Medical Sciences, Bathinda-151001 (Punjab) India*

Abstract

Coexistence of the Poland syndrome and gynaecomastia is a rare condition. Poland's syndrome itself is a rare anomaly which consists of unilateral absence or under development of pectoralis major muscle, hypoplasia of the breast, associated in some cases with a genesis of ipsilateral costal cartilages, athelia and ipsilateral webbing of the fingers. It has reported incidence of 1 in 7000-1 in 100,000 live births with a male preponderance (male: female ratio of 3:1). Gynaecomastia by contrast is the benign enlargement of breast tissue in males. Poland's syndrome is a rare congenital anomaly but co-occurrence of contralateral gynaecomastia is even rarer with only four cases reported till date. We report a 22-year-old male patient with right gynaecomastia and left sided Poland's syndrome. In order to correct his asymmetry on the anterior chest wall, liposuction and gland excision on the right side was done.

Keywords: Gynaecomastia, Poland's Syndrome, Liposuction

Introduction

Poland syndrome was defined by Sir Alfred Poland about 170 years ago. The incidence of Poland syndrome has been reported as 1/30000 [1]. Poland's syndrome is characterized by an absence or underdevelopment of the pectoralis muscles in combination with webbing of the fingers in the ipsilateral hand, which can be either complete or incomplete. Other deformities can include scoliosis, hypoplasia of the rib cage and lungs, upper extremity hypoplasia, breast and nipple hypoplasia, and deficiencies of the skin, subcutaneous tissues, sweat glands, and hair of affected areas. It has reported a male preponderance (male: female ratio of 3:1) [2-4].

Gynaecomastia is defined clinically as generalized enlargement of male breast tissue, with the presence of a rubbery or firm mass extending concentrically and symmetrically from the nipple [5]. Coexistence of gynaecomastia and Poland Syndrome in a patient is a rare condition. In the literature, three cases have been reported in

different publications with this condition globally [6] and this being the first case in India.

Case Report

A 22 year old patient reported to our out-patient department with chief complaints of increase in right sided chest size, he was not aware of presence of Poland's syndrome in him and absence of pectoralis major muscle on left side. On examination he was having gynaecomastia grade 2a according to classification given by Simon *et al.* [7]. Relevant investigations in the form of magnetic resonance imaging was done. Magnetic resonance imaging suggested left sided absence of pectoralis major and minor muscles and right sided gynaecomastia. Endocrinology consultation was taken and no hormonal disorder was found. No other anomaly was found. Surgery in the form of right side liposuction and left side fat grafting was recommended but patient voluntarily refused for left side fat grafting as his main concern was right

side chest enlargement only. After obtaining written informed consent, liposuction and gland excision of right side was planned. Patient was taken up for surgery and Tumescant fluid with 1000 ml normal saline, 50 ml 1% lidocaine and 1 ml 1:1000 adrenaline and 2.5 ml of 8.4% sodium bicarbonate, was infiltrated in the right chest area.

Liposuction was performed with standard Coleman technique. Gland excision was done with right inferior areolar semilunar incision. Post-operative period was uneventful and the patient was discharged the next day under satisfactory conditions (Figs. 1-3).

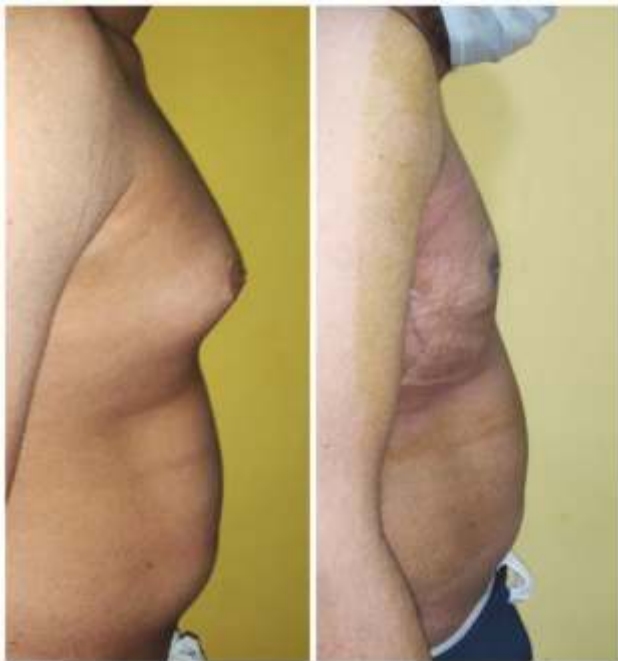

Figure 1: Lateral view (a) Pre-operative, (b) Post-operative

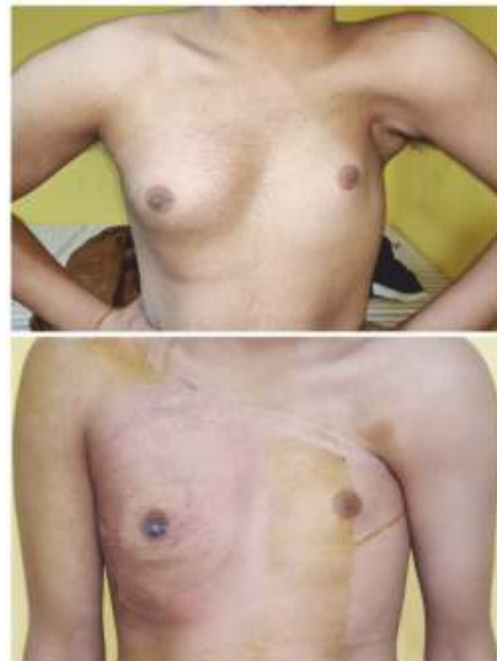

Figure 2: Front view (above) Pre-operative, Post-operative (below)

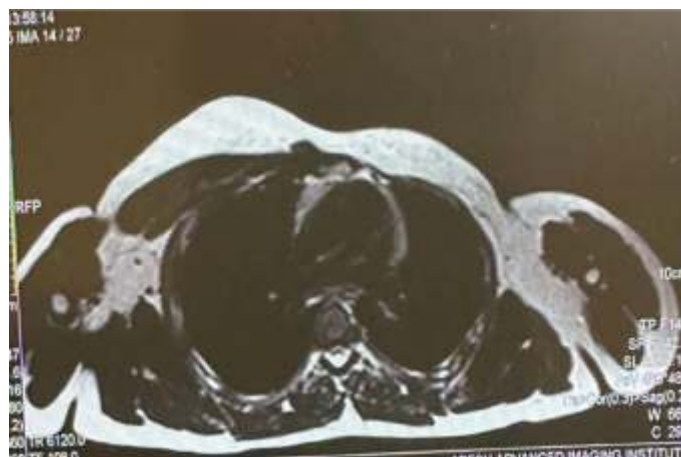


Figure 3: MRI image showing absence of pectoralis major on left side and gynecomastia on right side.

Discussion

Poland's syndrome is thought to be a consequence of developmental hypoxic insult between 6 and 8 weeks of gestation as the upper limb and chest musculature develops. It encompasses a spectrum of congenital anomalies, characterized by hypoplasia or a genesis of the pectoral muscles, breast, nipple areola complex, soft tissue and upper limb skeletal anomalies. It is usually unilateral. Gynaecomastia by contrast is a benign enlargement of breast tissue in males. In our case report gynaecomastia was on the right side and Poland's syndrome on left side whereas the study by Erkan *et al.* showed hypertrophic breast tissue on the left side and undeveloped breast tissue on the right side [8]. Ian *et al.* also reported 46 year old patient with right sided Poland' syndrome and left sided

gynaecomastia [9]. The main purpose of the reconstruction of Poland's syndrome with concurrent gynaecomastia is to provide as much symmetry as possible. Liposuction on gynaecomastia side and fat grafting on Poland's syndrome side remains the ideal treatment for such cases but as in our case where the patient refused for fat grafting, doing liposuction and gland excision alone can give satisfactory results.

Conclusion

We hereby report a case of Poland's syndrome with co-existing gynaecomastia of contralateral side which was treated with liposuction and gland excision and was discharged under satisfactory conditions. On follow-up after 5 months, the patient had no complaints and was doing fine.

References

1. Chest Wall Deformities. Townsend CM, Beauchamp DR, Evers MB, Mattox KL. Townsend. Sabiston Textbook of Surgery: 18th ed. Chapter 57. Philadelphia: WB Saunders-Elsevier; 2008.
2. Greydanus DE, Parks DS, Farrell EG. Breast disorders in children and adolescents. *Pediatr Clin North Am* 1989; 36(3):601-638.
3. Arca MJ, Caniano DA. Breast disorders in the adolescent patient. *Adolesc Med Clin* 2004;15(3): 473-85.
4. Moir CR, Johnson CH. Poland's syndrome. *Semin Pediatr Surg* 2008;17(3):161-166.
5. Braunstein GD. Clinical practice. Gynecomastia. *N Engl J Med* 2007; 357(12):1229-1237.
6. Mahoney J, Hynes B. Concurrent Poland's syndrome and gynecomastia: a case report. *Can J Surg* 1990; 33(1):58-60.
7. Simon BE, Hoffman S, Kahn S. Classification and surgical correction of gynecomastia. *Plast Reconstr Surg* 1973;51(1):48-52.
8. Yüce E, Şirvan SS, Demir IA, Eren HI, Karşıdağ S. Coexistence of Gynecomastia and Poland Syndrome: Case Report. *Sisli Etfal Hastan Tip Bul* 2019;53(3): 314-317.
9. King ICC, Fung V, Dunkin CSJ. Concurrent Poland's syndrome and gynaecomastia: achieving the balance using lipomodelling. *Eur J Plast Surg* 2015; 38: 237-240.

*Author for Correspondence:

Dr Saurabh Gupta, Kothi no 272, Model town, Phase-1, Bathinda-151001, Punjab, India Cell: 9909914670
Email: ssgbti@gmail.com

How to cite this article:

Gupta S. A rare case of Poland's syndrome with contralateral gynaecomastia: A case report. *J Krishna Inst Med Sci Univ* 2022; 11(4):84-86

Submitted: 23-June-2022 Accepted: 10-Sep-2022 Published: 01-Oct-2022