
ORIGINAL ARTICLE**Supratrochlear Foramen of Humerus - A Morphometric Study with Surgical and Radiological Relevance**

Gyanaranjan Nayak¹, Biswa Bhusan Mohanty¹, Niranjana Sahoo^{2*}, Saurjya Ranjan Das¹,
Sitansu Kumar Panda¹, Prafulla Kumar Chinara¹

¹Department of Anatomy, ²Department of Forensic Medicine and Toxicology, IMS and SUM Hospital,
Siksha 'O' Anusandhan (Deemed to be University), Bhubaneswar- 751003 (Odisha) India

Abstract:

Background: The supratrochlear foramen is a common anatomical variation in the lower end of human humerus with significant surgical implication. The present study was carried out to assess the supratrochlear foramen morphologically and morphometrically and highlight the clinical utility of the findings. **Material and Methods:** The study included sixty dried, unpaired, adult human humeri (28 right and 32 left). They were studied macroscopically for the incidence, dimensions, location and shape of the supratrochlear foramina. **Results:** Twelve bones (20%) showed supratrochlear foramen (7 on left side and 5 on right side). The transverse diameter of the foramen was measured to be 6.57 ± 2.50 mm on left side and 5.0 ± 1.58 mm on right side. The vertical diameter of the foramen was found to be 5.28 ± 1.60 mm on left side and 3.20 ± 0.83 mm on right side. The distance of the foramen from lateral epicondyle and medial epicondyle of humerus was determined to be 25.16 ± 2.28 mm and 23.58 ± 2.23 mm respectively. The foramina exhibited various shapes- irregular, rectangular, hour glass like, triangular and oval. **Conclusion:** The supratrochlear foramen is important for orthopaedicians as it can predispose to fracture of distal humerus. Requisite planning is necessary for the intramedullary nailing of the fractures of distal humerus due to associated narrow medullary canal in humerus having supratrochlear foramen. Radiologists may misinterpret it as a cystic or lytic lesion of humerus.

Keywords: Supratrochlear foramen, Supracondylar fracture, Intramedullary Nailing

Introduction:

The coronoid and olecranon fossae of lower end of humerus are separated by a thin septum. This septum may be perforated to form an aperture variously known as supratrochlear foramen, supratrochlear aperture, intercondylar foramen or epitrochlear foramen [1-3]. A thin plate of compact bone is present between the coronoid and olecranon fossae which occasionally gets absorbed to form supratrochlear foramen after the age of 7 years [4]. Apart from humans, the foramen has been observed in other mammalian species like hyenas, dogs and more so in old and new world apes [5,6]. Darwin considered the presence of supratrochlear foramen in humans as a proof of evolution of humans from lower primates [5]. Beyond its evolutionary and anthropological relevance, supratrochlear foramen has significant surgical and radiological importance. The bony defect acts as a stress riser and plays significant role in altering fracture patterns of lower end of humerus and in selecting its proper management [7]. Supratrochlear foramen increases susceptibility to fracture on the humeri bearing its secondary to a selective low energy or innocuous trauma [7]. Radiologists may erroneously

interpret the supratrochlear foramen as a cystic or osteolytic lesion of the lower end of humerus [3]. The present study was carried out to evaluate the supratrochlear foramen morphologically and morphometrically as the said anatomical variation greatly influences orthopaedic and radiological practice.

Material and Methods:

The study was conducted in the Department of Anatomy of Medical College in Bhubaneswar, Odisha, India. We studied sixty adult, dried, unpaired human humeri (28 right and 32 left) macroscopically for the presence, morphology and morphometry of supratrochlear foramen. Broken, deformed bones and bones with pathological changes were excluded from the study. The shape of the foramen was noted and imaged. The vertical and transverse diameters of the supratrochlear foramen were measured with a digital Vernier calliper. The distances of the foramen from humeral epicondyles were also measured. All the measurements were repeated twice by two different observers to exclude interobserver variation. Lower ends of the bones without the supratrochlear foramen were subjected to transmitted light from posterior surface to anterior to find out the translucency of the septum between coronoid and olecranon fossae. All the observations were tabulated using Microsoft Excel software. The following criteria were used to determine the sex of the bones.

(A) The length of the humerus is 32.5 cm in males and 30 cm in females. The vertical diameter of the head of humerus is 48.7 mm in males and 41.5 mm in females. The transverse diameter of the head of humerus is 44.6 mm in males and 38.9 mm in females [8].

(B) Maximum diameter of head of humerus is more than 47 mm in males and less than 43 mm in females [9].

Results:

The study included 28 right (46.6%) and 32 left (53.3%) humeri. Twelve humeri (20%) showed the presence of supratrochlear foramen. Seven humeri (11.6%) with supratrochlear foramen belonged to left side and five humeri (8.33%) belonged to right side (Table 1). Majority of the foramina (58.33%) were of irregular shape (Fig. 1 a, b, c). Two foramina (16.66%) were rectangular in shape (Fig. 2). Hourglass like shape (Fig. 3), triangular shape (Fig. 4) and oval shape (Fig.5) were observed in one humerus each. The frequency of various shapes is reported in Table 1. The mean transverse diameter of the foramen was 6.57 ± 2.50 mm on left side and 5.0 ± 1.58 mm on right side. The mean vertical diameter of the foramen was 5.28 ± 1.60 mm on left side and 3.20 ± 0.83 mm on right side. The mean Distance between the Foramen and Lateral Epicondyle (DFLE) of humerus was 25.16 ± 2.28 mm whereas the Distance between the Foramen and Medial Epicondyle (DFME) of humerus was 23.58 ± 2.23 mm. Twenty three bones (38.33%) showed translucency of the septum between coronoid fossa and olecranon fossa. Out of them twelve bones (20%) belonged to left side and eleven (18.33%) belonged to right side. Figure 6 shows a humerus with translucent septum between coronoid and olecranon fossae. Only two out of twelve humeri showing supratrochlear foramen belonged to males. Rest ten humeri with supratrochlear foramen belonged to females.

Table 1: Showing Shape of Supratrochlear Foramen

Shape of supratrochlear foramen	Number (Percentage)
Irregular	7 (58.33)
Rectangular	2 (16.66)
Hourglass like	1 (8.33)
Triangular	1 (8.33)
Oval	1 (8.33)

Table 2: Comparison of Transverse and Vertical Diameters of Supratrochlear Foramen of Various Authors with Current Study

Authors	Left side Transverse Diameter (mm)	Left side Vertical Diameter (mm)	Right side Transverse Diameter (mm)	Right side Vertical Diameter (mm)
Krishnamurthy <i>et al.</i> [18]	6.50 ± 2.59	4.70 ± 1.69	5.26 ± 2.47	4.0 ± 1.52
Nayak <i>et al.</i> [19]	6.55 ± 2.47	4.85 ± 1.64	5.99 ± 1.47	3.81 ± 0.97
Mathew <i>et al.</i> [20]	4.88 ± 1.63	3.37 ± 1.25	5.24 ± 1.76	3.82 ± 1.07
Current study	6.57 ± 2.50	5.28 ± 1.60	5.0 ± 1.58	3.20 ± 0.83

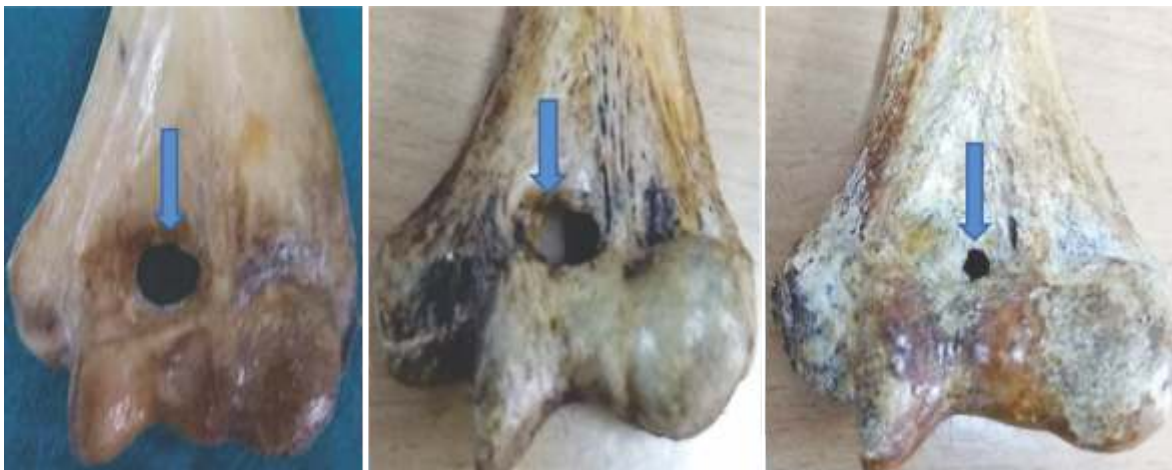

Fig. 1a, b, c: Supratrochlear Foramen having Irregular Shape



Fig. 2: Supratrochlear Foramen having Rectangular Shape

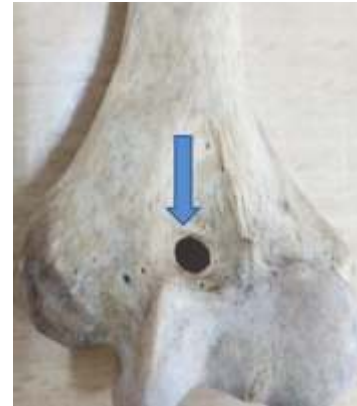


Fig. 5: Supratrochlear Foramen having Oval Shape

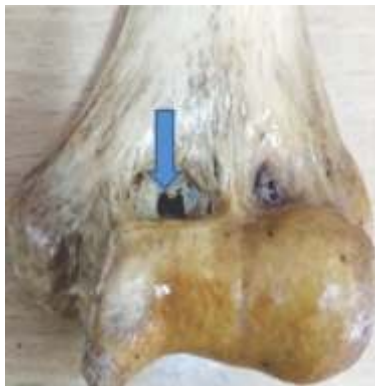

Fig. 3: Supratrochlear Foramen having Hourglass like Shape

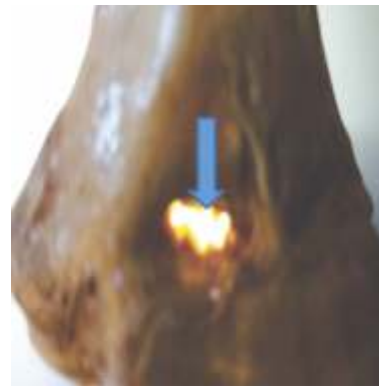

Fig. 6: Humerus showing Translucency of Septum between Olecranon and Coronoid Fossa

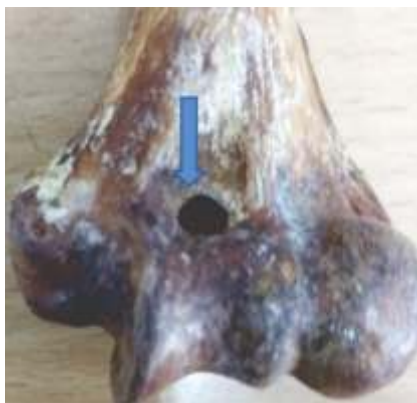

Fig. 4: Supratrochlear Foramen having Triangular Shape

Discussion:

The supratrochlear foramen is a relatively common variation in the distal end of humerus. The supratrochlear foramen was found to be present in 20% humeri in the current study. Our findings are comparable with other authors [2, 10-20]. The frequency of supratrochlear foramen in the current study is higher in females and more common on left side. This finding is similar to other authors [2, 3, 12, 17-18]. However, Nayak *et al.* [19] have reported supratrochlear foramen to

be more common on right side. The transverse and vertical diameters of the supratrochlear foramen obtained in the current study are compared with other authors [18, 19, 20] in Table 2.

Maximum numbers of foramina were of irregular shape followed by rectangular shape. In the current study, we got foramina of hourglass like, triangular and oval shape as well similar to earlier studies [3, 19, 20]. But hour glass like shape of supratrochlear foramen has never been reported till date. The current study has established that the supratrochlear foramen is located nearer to the medial epicondyle as proposed by other authors [3, 19-21].

The frequency of translucency of the septum between coronoid and olecranon fossae was observed to be almost similar on left and right side. This is consistent with the findings of Krishnamurthy *et al.* [18] and Mathew *et al.* [20]. Foramina by definition act as conduits for vessels and nerves. Apertures, on the other hand are mere defects in bones and don't transmit vessels and nerves [12]. The supratrochlear foramen doesn't give passage to any neurovascular structures and should be better designated as apertures.

Various theories are proposed to explain the formation of supratrochlear foramen. The supratrochlear foramina are supposed to be formed by a combination of overgrown coronoid and olecranon processes and hyperextension in lax and highly mobile elbow joints. Ulnae from elbow joints with supratrochlear foramina are reported to be having larger olecranon process and smaller coronoid process with wider and deeper olecranon fossae. Such humeri also exhibit smaller and less curved articular surfaces [21]. Lax joints being hypermobile lead to impingement of olecranon

and coronoid processes of the ulnae on humeral laminae resulting in laminar perforation and formation of supratrochlear foramina [13, 22, 23]. The mechanical theory of formation of supratrochlear foramen is supported by the proposition that the foramina are more prevalent in weaker and lighter bones [24-26]. Supratrochlear foramina are less frequently found in robust humeri [5]. Benfer and Mc Kern [2] have established that more robust humeri have smaller mean percentages of septal perforation using minimum middle diameter of humerus as a quantitative determinant of bone robusticity. The higher frequency of supratrochlear foramina in females and nondominant extremity in our study finds a probable explanation in the mechanical hypothesis of septal perforation of humerus discussed above.

However the likes of Myszka and Trzcinski [27] have contradicted the mechanical hypothesis. They found that septal foramina did not correlate with bony spurs (osteophytes) and eburnation and opine that overgrown bony processes may not be responsible for the formation of apertures in bones impinged upon by them.

The knowledge of supratrochlear foramina is highly relevant in surgical practice. The supratrochlear foramen may act as a stress riser resulting in supracondylar fracture of humerus [7]. The periosteum, ligaments and fibrous capsule around the elbow joint being intact the fracture remains stable as proposed by Kuhn *et al.* [28]. On the other hand, Sahajpal and Pichora [7] have put forward that a more rigid fixation of these supracondylar fractures of humerus should be done with multiple construction plates with or without lag screw as these fractures are rotationally unstable.

The supracondylar fractures are very common in the paediatric age group [19] and they are treated by intramedullary nailing [3]. The retrograde nailing is done through medial and lateral epicondyles of humerus [3]. Apkinar *et al.* [29] have reported humeri with septal aperture having very narrow medullary canal. Parakevas *et al.* [30] have concluded that the distal portion of medullary canal in humeri with septal aperture was narrower and shorter than humeri without the aperture which can result in secondary fractures during retrograde intramedullary nailing. So they advocate to avoid surgical procedure and perform an antegrade medullary nailing if need for surgery arises.

The supratrochlear foramina are very important in interpreting regular skiagrams of upper limb. The supratrochlear foramen being relatively radiolucent may be confused as lytic or cystic lesions in radiographs [20].

The formation of septal humeral aperture finds a probable genetic basis. Chapman *et al.* and Govoni *et al.* have indicated a possible role of T-Box (TBX) genes in the formation of supratrochlear foramen [20]. The TBX proteins produced by this gene are crucial for development of limbs in utero as well as during postnatal life.

Conclusion:

The supratrochlear foramen is a very common variation in the anatomy and physical anthropology. But it finds scarce mention in clinical practice text. However, the knowledge of its presence is essential in orthopaedic surgery and radiologic practice. Ours being a dry bones study, we recommend cadaveric and radiologic studies of supratrochlear foramen for its better elucidation.

References

1. Das S. Supratrochlear foramen of the humerus. *Anat Sci Int* 2008; 83:120.
2. Benfer RA, Mc Kern TW. The correlation of bone robusticity with the perforation of the coronoid-olecranon septum in the humerus of man. *Am J Phy Anthropol* 1966; 24(2): 247-52.
3. Ndou R, Smith P, Gemell R, Mohtala O. The supratrochlear foramen of the humerus in a South African dry bone sample. *Clin Anat* 2013; 26: 870-74.
4. Morton HS, Crysler WE. Osteochondritis dessicans of the supratrochlear septum. *J Bone Joint Surg Am* 1945; 27: 12-24.
5. Benfer RA, Tappen NC. The occurrence of the septal perforation of the humerus in three non-human primate species. *Am J Phys Anthropol* 1968; 29: 19-28.
6. Hazirolu KM, Ozer M. A supratrochlear foramen in the humerus of cattle. *Anat Histol Embryol* 1990; 19: 106-8.
7. Sahajpal D, Pichora D. Septal aperture: an anatomic variant predisposing to bilateral low-energy fractures of distal humerus. *Can J Surg* 2006; 49(5): 363-4.
8. Karmakar RN. Bones. In: Forensic Medicine and Toxicology; 1st edn, Academic Publisher, Calcutta. 2006: 20.
9. Reddy KSN, Murty OP. Identification. In: The essentials of Forensic Medicine and Toxicology; 34th edn, Jaypee Brothers Medical Publisher, New Delhi. 2017: 62.
10. Kate BR, Dubey PN. A note on the septal aperture in the humerus of Central Indians. *East Anthropol* 1970; 33: 105-10.
11. Hirsch IS. The supratrochlear foramen: Clinical and Anthropological Considerations. *Am J Surg* 1927; 2: 500-5.
12. Glanville EV. Perforation of the coronoid-olecranon septum. Humero-ulnar relationships in Netherlands and African populations. *Am J Phy Anthropol* 1967; 26: 85-92.
13. Papaloucas C, Papaloucas M, Stergioulas A. Rare cases of humerus septal apertures in Greeks. *Trends Med Res* 2011; 6: 178-83.

14. Akabori E. Septal apertures in the humerus in Japanese, Ainu and Koreans. *Am J Phys Anthropol* 1934;18: 395-400.
15. Ming-Tzu P. Septal apertures in the humerus in Chinese. *Am J Phys Anthropol* 1935; 20:165-70.
16. Chattarjee KP. The incidence of perforation of olecranon fossa in the humerus among Indians. *East Anthropol* 1968; 21:279-84.
17. Singh S, Singh SP. A study of supratrochlear foramen in the humerus of North Indians. *J Anat Soc India* 1972; 21:52-6.
18. Krishnamurthy A, Yelicharla AR, Takkalapalli A, Munishamappa V, Bovinndala B, Chandramohan M. Supratrochlear foramen of humerus: a morphometric study. *Int J Biol Med Res* 2011; 2(3): 829-31.
19. Nayak SR, Das S, Krishnamurthy A, Prabhu LV, Potu BK. Supratrochlear foramen of the humerus: an anatomico-radiological study with clinical implications. *Ups J Med Sci* 2009; 114(2): 90-4.
20. Mathew AJ, Gopidas GS, Sukumaran TT. A study of the supratrochlear foramen of the humerus: anatomical and clinical perspective. *J Clin Diagn Res* 2016; 10(2): AC05-8.
21. Kubicka AM, Myszka A, Pointek J. Geometric morphometrics: does the appearance of the septal aperture depend on the shape of ulnar processes? *Anat Rec (Hoboken)* 2015; 298(12): 2030-38.
22. Mays S. Septal apertures of the humerus in a Medieval human skeleton population. *Am J Phys Anthropol* 2008; 136(4): 432-40.
23. Myszka A. Septal aperture aetiology still more questions than answers. *Folia Morphol (Warsz)* 2015; 74(2): 219-24.
24. Hrdlicka A. The humerus septal aperture. *Anthropologie (Prague)* 1932; 10: 51-96.
25. Trotter M. Septal aperture in the humerus of American Whites and Negroes. *Am J Phys Anthropol* 1934; 1: 213-27.
26. Silveira FBC, Junior VM, Fazen VPS. Anthropometric evaluation of the humerus in the presence and absence of septal foramen. *Int J Morphol* 2007; 25:158.
27. Myszka A, Trzcinski D. Septal aperture and osteoarthritis-the same or independent origins. *Adv Anthropol* 2015; 5(2); 116-21.
28. Kuhn JE, Lois DS, Lord RT. Divergent single column fractures of the distal part of the humerus. *J Bone Joint Surg Am* 1995; 77(4): 538-42.
29. Akpınar F, Aydinlioğlu A, Tosun N, Doğan A, Tuncay I, Unal O. A morphometric study of the humerus for intramedullary fixation. *Tohoku J Exp Med* 2003; 199(1): 35-42.
30. Parakevas G, Papazlogs B, Tzaveas A, Giaglis G, Kitsoulis P, Natsis K. The supratrochlear foramen of the humerus and its relation to the medullary canal: A potential surgical application. *Med Sci Monit* 2010; 16(4): BR119-23.

***Author for Correspondence:** Dr Niranjana Sahoo, Department of Forensic Medicine and Toxicology, I M S and SUM Hospital, Siksha 'O' Anusandhan (Deemed to be University), K 8, Kalinga Nagar, Bhubaneswar- 751003, Odisha, India Email: nira.cuttack@gmail.com Cell: +919438274384