
CASE REPORT**Trigger Hallux: A Rare Case of Stenosing Tenosynovitis of Flexor Hallucis Longus in a Ballet Dancer (Hallux Saltans)**

Mohd Fadhli Miskon², Mohd Yazid Bajuri^{1*}, Abdul Muhaimin Ali¹, Azammuddin Alias³, Srijit Das⁴

¹Department of Orthopaedic & Traumatology, Faculty of Medicine, Universiti Kebangsaan Malaysia Medical Centre, 56000 Kuala Lumpur, Malaysia, ²Department of Orthopaedic, Hospital Sultan Ismail, 81100, Johor Bahru, Malaysia, ³Department of Orthopaedic, Hospital Tuanku Jaa'far, 70300, Negeri Sembilan, Malaysia, ⁴Department of Anatomy, Faculty of Medicine, Universiti Kebangsaan Malaysia Medical Centre, 56000 Kuala Lumpur, Malaysia

Abstract:

Triggering of the big toe is an uncommon presentation. Here we present a case of a ballet dancer complaint of pain along the posteromedial aspect of the left ankle, associated with triggering of her big toe. To our knowledge, there have not been any reports on the above condition in our region. With changing of lifestyle and demand of the population, clinicians should be aware of this, therefore appropriate management and treatment can be given.

Keywords: Trigger Hallux, Stenosing Tenosynovitis, Hallux Saltans

Introduction:

Trigger hallux is a rare condition. It is due to entrapment of Flexor Hallucis Longus (FHL) within the fibroosseous canal underneath the sustentaculum tali or at the flexor retinaculum. It is commonly seen in ballet dancers due the position of the foot (*'en pointe'*) during dancing that puts enormous pressure to FHL tendon. Repetitive position and pressure results in tenosynovitis, hypertrophy of the FHL muscles as well and formation of thickened nodule within the tendon. The aim of this report is to highlight this extremely rare, or under reported case, in our region.

Case Report:

A 24 year-old female professional ballet dancer was complaint of triggering of her left big toe for the past 6 months. She described a clicking sensation on flexion of the big toe and snapping upon extending it. It was associated with pain on the medial aspect of the foot, which radiates along the posteromedial part of her ankle. The pain becomes more severe during jumping and when she attempted to stand *'en pointe'* position during ballet. Upon examination, there was a palpable nodule which is non tender at the back of the left medial malleolus and a classical triggering on active extension of the left big toe (Fig. 1). Ultrasound revealed thickened Flexor Hallucis Longus (FHL) tendon posterior to the left medial malleolus compared to the contralateral side. Magnetic resonance imaging of left ankle revealed homogenous nodular thickening of the FHL tendon (Fig. 2). There was no tendon degeneration or synovial changes noted.

We proceed with surgical release in which a posteromedial incision was made along the course of the FHL tendon behind the medial malleolus. Flexor retinaculum was identified and released.

Neurovascular bundle was identified and tagged. Intraoperative findings showed low-lying with hypertrophy of the flexor hallucis longus muscle. There is a nodular thickening of the FHL tendon, just proximal to flexor retinaculum. There was no evidence of synovitis along the FHL tendon sheath and no evidence of thickening of the tendons at the Knot of Henry. Post operatively she

was put on a posterior slab for 6 weeks. Rehabilitation process started after 6 weeks, with gradual range of motion and muscle strengthening exercise. She was allowed to resume her ballet dancing after 3 months. On final follow up she was able to resume the position of 'enpointe' with no more triggering of the big toe and pain free (Fig. 3).

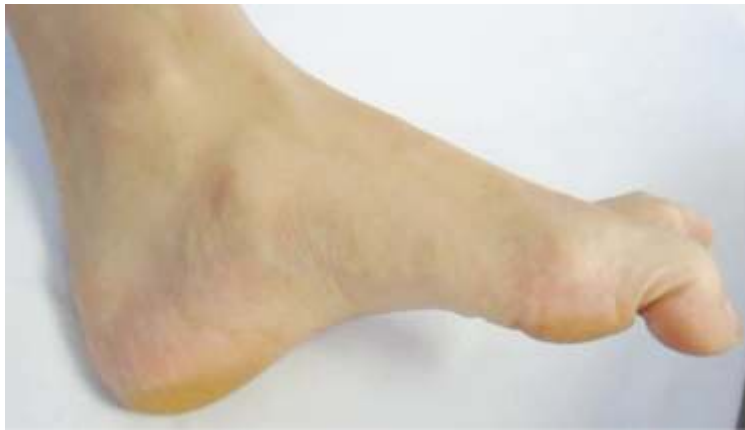

Fig. 1: Flexion Attitude of the Big Toe

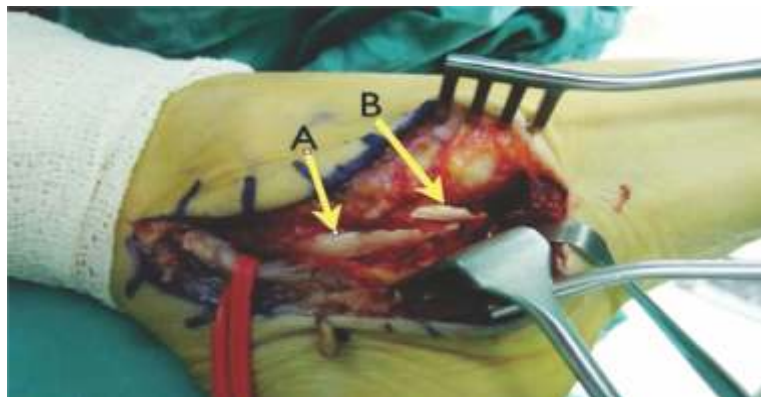


Fig.2: Operative Findings: A) Nodular Thickening of FHL Tendon B) Normal Appearance of FHL and FDL Tendons at the Knot of Henry

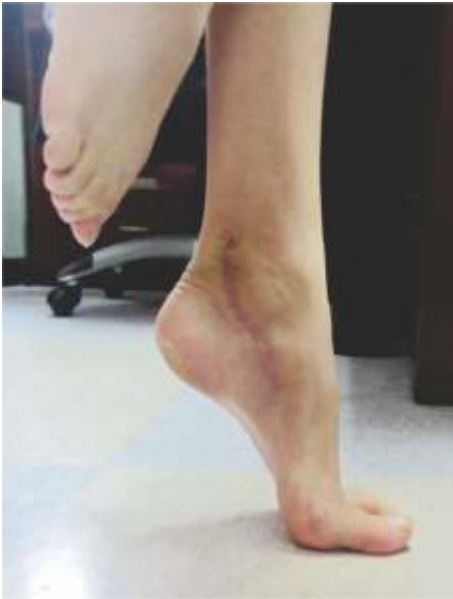

Fig. 3: Six Month Post Operative Patient Able to Resume Position of 'en pointe'

Discussion:

Triggering of the big toe is rare, not commonly seen in our general population. It is usually unilateral however bilateral involvements have been reported. If it happens it is almost always occur in skilled individual that requires repetitive tip toeing position during the course of activities such as professional ballet dancers, less commonly in tennis players and runners [1, 2]. As far as the authors are concern, this condition has not been reported in our region. The rarity of trigger hallux increases the possibility of misdiagnosing the condition thus delaying the treatment.

The site of which the FHL might become entrapped varies. It can happen along the course of the tendon as it travels from deep posterior compartment of the calf to its attachment distally. Ostrigonum or steida process may contribute to entrapment of FHL as it travels in between lateral and medial tubercles of talus. As it goes beyond talus, FHL tendon enters a fibro osseous tunnel

beneath the sustentaculum tali. Here the entrance of the tunnel is the commonest site of entrapment [2]. The next possible site for entrapment is the master Knot of Henry, in which the FHL and FDL tendon crosses close to each other. Distally, as it nears its attachment, entrapment of FHL tendon can happen between the medial and lateral sesamoid bone within the FHB tendon.

History taking is somewhat important in diagnosing Hallux Saltans. Trigger hallux is mainly described in ballet dancer [3]. The repetitive 'en pointe' position puts extremely high stress to the FHL tendon that leads to tenosynovitis, predisposed to nodule formation and entrapment. This may be the reason why trigger hallux is seen in ballet dancers. Runners who have the habit of running on forefoot maybe prone to develop FHL tendinitis which can lead to this condition.

There are a few conditions that can be related or be one of the differential diagnoses in this kind of problem such as Volkmann's ischemic contracture, compartment syndrome over the left calf and inactive Extensor Hallucis Longus. Most of these conditions are treated surgically by releasing the tendon over the contracture site.

Lapidus in 1950 was the first to describe surgical release of Hallux Saltans [4]. Surgical release of entrapment in other site (ostrigonum, stedia process etc) has also been reported before. As in our case we noted the site of entrapment was within the flexor retinaculum behind medial malleolus of left ankle in which quite rarely seen. Rajesh *et al.* was the only paper that reported similar findings as us, in a manual laborer who has no predisposing factors [5]. In this case report, we presented a case of Hallux Saltans in a ballet dancer, not commonly seen in our region, due to FHL entrapment in an uncommon site.

References

1. Moorman 3rd CT, Monto RR, Bassett 3rd FH. So-called trigger ankle due to an aberrant flexor hallucis longus muscle in a tennis player. A case report. *JBJS* 1992;74(2):294-5.
2. Berglund CL, Philipps LE, Ojofeitimi S. Flexor hallucis longus tendinitis among dancers. *Orthopaed Phy Ther Pract* 2006; 18(3):26.
3. Kennedy JG, Hodgkins CW, Colombier JA, Guyette S, Hamilton WG. Foot and ankle injuries in dancers. *Int Sport Med J* 2007; 8(3):141-65.
4. Kolettis GJ, Micheli LJ, Klein JD. Release of the flexor hallucis longus tendon in ballet dancers. *JBJS* 1996; 78(9):1386-90.
5. Purushothaman R, Karuppal R, Inassi J, Valsalan R. Hallux saltans due to flexor hallucis longus entrapment at a previously unreported site in an unskilled manual laborer: a case report. *J Foot Ankle Surg* 2012; 51(3):334-6.

**Author for Correspondence: Mohd Yazid Bajuri, Department of Orthopaedic & Traumatology, Faculty of Medicine, Universiti Kebangsaan Malaysia Medical Centre, 56000, Kuala Lumpur, Malaysia
Email: ezeds007@yahoo.com.my Phone number: +60172771000*