

## ORIGINAL ARTICLE

**Henle's Spine - an Anatomical Landmark for Approaching Various Foramina in the Base of Skull***Senthil Kumar B<sup>1\*</sup>, Vijaya Kumar J<sup>2</sup>*

<sup>1</sup>Department of Anatomy, Vinayaka Mission's Kirupananda Variyar Medical College and Hospital, Salem-636308 (Tamil Nadu) India, <sup>2</sup>Department of Anatomy, Saveetha Medical College, Chennai-602105 (Tamil Nadu) India

**Abstract:**

**Background:** Surface landmarks of the temporal bone are related to various anatomical structures. The surgical exposure of the middle cranial fossa, transpetrosal and transmastoid approaches for skull base surgeries would require identification of various surface landmarks for approaching the structures. **Aim and Objectives:** To determine whether Henle's spine could be used as a reliable and multipurpose landmark for the important structures and foramen of the skull base during surgeries. **Materials and Methods:** This study was done on 170 dry human skulls. Two imaginary lines and a parapetrosal triangle was constructed which encompasses nearly all the main structures and foramina of the skull base. The distance from the Henle's spine to certain useful surgical landmarks on the skull base was measured and tabulated. **Results:** The measurements were analysed and compared by student's 't' test both the sides and found to be have slight variations in the measurements of right and left. Distance from Henle's spine to stylomastoid foramen and jugular foramen were found to high when compared to earlier studies other measurements showed only a slight deviations. **Conclusion:** Henle's spine when present (85%) can be used as a reliable anatomical landmark for approaching various foramina during skull base surgeries when other land mark fails.

**Keywords:** Metal spine, surgical landmarks, Foramen Spinosum, Foramen Ovale, Jugular Foramen, Foramen Lacerum, Carotid Canal, Hypoglossal Canal, Stylomastoid Foramen

**Introduction:**

The base of the skull base was quiet complex region having many neural and vascular structures that are connected with the cranial fossae, paranasal sinus, nasal cavity, orbit and the neck. Those structures are surgical challenges for the otolaryngologists and the neurosurgeons [1, 2]. Otologic and neurologic skull base surgery requires a thorough knowledge of the anatomy of temporal bone, as the temporal bone is one of the main approach for the skull base surgery [3]. Surface landmarks of the temporal bone was related to the neighboring structures and the underlying anatomical framework. The surgical exposure of the middle cranial fossa, transpetrosal and transmastoid approaches for skull base surgeries requires the identification of the surface anatomic landmarks. The petrous part of temporal bone gives passage for various important neurovascular structures such as internal carotid artery, vestibulocochlear nerve and facial nerve [4]. To identify and safely approach and manipulate the vital structures in the skull base surgeries, various anatomical surface landmarks like mastoid tip, styloid process, spine of sphenoid, spine of Henle, Macewan's triangle, the cribriform plate, tympanic plate, articular tubercle, temporal line, external auditory canal and the root of the zygoma [2] were used to correlate and access the underlying anatomical

structures.

Henle's Spine (HS)/ spina suprameatica/ spina suprameatalis/ meatal spine or spina meatus, is a small bony prominence anterior to the supramastoid pit at the postero- superior margin of the bony external acoustic meatus. Jacob Henle reported it as a reliable guide in locating the antrum during the surgical intervention of the mastoid region [5]. The HS, when present, because of its superficial and key position could be an important surface landmark to identify the structures of the cranial base. Considering the key position, superficial accessibility and the clinical importance [6], present study was carried out to estimate the distance from the HS to certain useful surgical landmarks on the skull base such as foramen spinosum, F. ovale, F. lacerum, carotid canal, stylomastoid foramen and jugular foramen on the dry adult South Indian skulls. To determine whether Henle's spine could be used as a reliable and multipurpose landmark for the important structures and foramen of the skull base and also to determine the distance from the HS to certain useful surgical landmarks and foramina on the skull base.

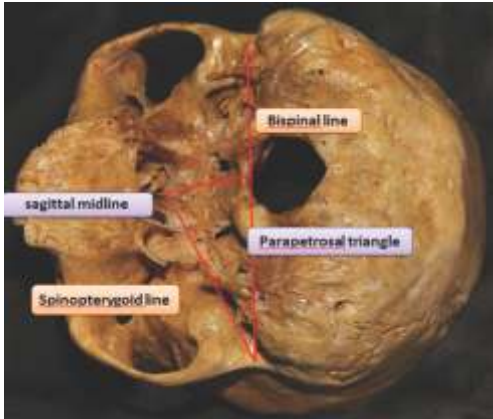
#### **Materials and Methods:**

The study was approved by Institutional Ethics Committee (VMKVMC/IEC/16/80) of Vinayaka Mission's Kirupananda Variyar Medical College, Salem. This observational study was carried out at VMKV Medical College and Penang International Dental College, on 200 dry human skulls of unknown age and sex in the department of anatomy out of which 170 skulls were found to have HS (85%). The measurement was taken after constructing two imaginary lines and a triangle. An imaginary spinopterygoidal line extending from Henle's spine to the root of the right medial

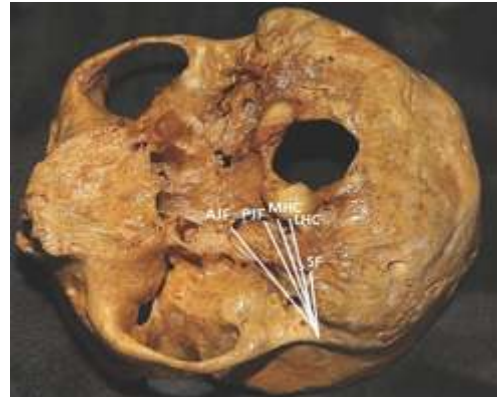pterygoid plate (left pterygoid plate when measured on left side), an imaginary bispinal line extending from one HS to the contralateral one, and an imaginary parapetrosal triangle lying between the spinopterygoidal line, the bispinal line and the sagittal midline was thus constructed (Fig. 1). The parapetrosal triangle encompasses nearly all the main structures of the skull base. The distance from the HS to foramen spinosum, foramen ovale with its anterior and posterior margin (Fig. 2), jugular foramen with its anterior and posterior margin (Fig. 3), foramen lacerum with its anteromedial and posterolateral margin, carotid canal with its medial and lateral margin (Fig. 4), hypoglossal canal with its medial and lateral margin and stylomastoid foramen (Fig. 3) were measured by Vernier caliper and tabulated [4, 5]. The mean, standard deviation, Standard Error Mean (SEM) and range were calculated. The data was analyzed by t test for comparison on the right and left side measurements. Statistical analysis was done using SPSS software.

#### **Results:**

The mean and SEM from the HS to various important anatomical landmarks on the spinopterygoidal and bispinal lines and in the parapetrosal triangle were measured and tabulated (Tables 1–3) (Fig. 1). Statistical differences between the two sides were tabulated which showed significant difference only in the distance between the HS to the lateral margin of the external orifice of carotid canal, stylomastoid foramen and posterior margin of jugular foramen (Tables 2 and 3) (Fig. 5) shows the graphical presentation of distance from HS to various foramen of skull base.

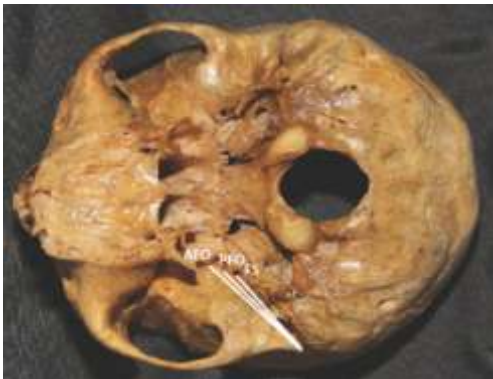

**Fig.1: Parapetrosal Triangle**



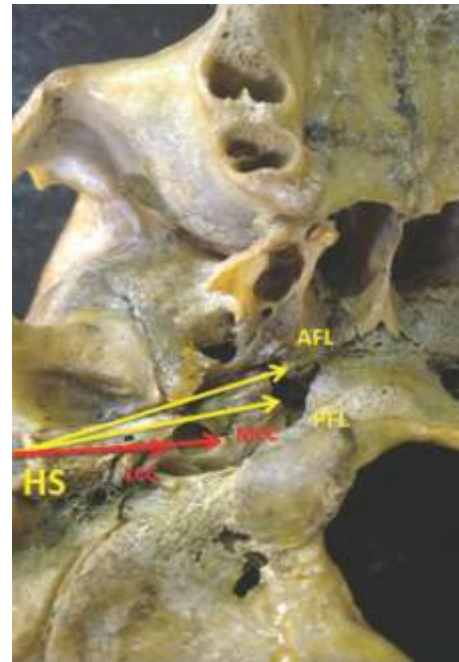
*AJF – Anterior Margin of Jugular Foramen,  
PJF - Posterior Margin of Jugular Foramen,  
MHC- Medial Margin of Hypoglossal Canal,  
LHC - Lateral Margin of Hypoglossal Canal,  
SF- Stylomastoid Foramen*

**Fig.3: Measurements from Henle's Spine to Jugular Foramen, Hypoglossal Canal and Stylomastoid Foramen**



*AFO – Anterior Margin of Foramen Ovale,  
PFO - Posterior Margin of Foramen Ovale,  
FS- Foramen Spinosum*

**Fig.2: Measurements from Henle's Spine to Foramen Ovale and Spinosum**



*AFL – Anterior Margin of Foramen Lacerum,  
PFL – Posterior Margin of Foramen Lacerum,  
MCC – Medial Margin of Carotid Canal,  
LCC – Lateral Margin of Carotid Canal*

**Fig.4: Measurements from Henle's Spine to Foramen Lacerum and Carotid Canal**

**Table 1: Distance between Henle's Spine to Foramen Spinosum, Ovale and Lacerum**

Side	Foramen Spinosum Mean ± SEM (cm)	Foramen Ovale Mean ± SEM (cm)		Foramen Lacerum Mean ± SEM (cm)	
		Anterior	Posterior	Anteromedial	Posterolateral
<b>Right</b>	3.44±0.02	4.37±0.3	3.78±0.02	5.07±0.03	4.60±0.04
<b>Left</b>	3.45±0.03	4.40±0.4	3.77±0.04	5.03±0.03	4.58±0.03
<b>P value</b>	0.78	0.95	0.83	0.35	0.69

Values are expressed as Mean ± SEM, n = 170, \* - significant, \*P < 0.05.

**Table 2: Distance between Henle's Spine to Hypoglossal and Carotid Canal**

Mean Distance	Hypoglossal Canal (cm) Mean ± SEM		Carotid Canal (cm) Mean ± SEM	
	Medial	Lateral	Medial	Lateral
<b>Right</b>	4.27±0.04	3.92±0.03	3.44±0.03	2.95±0.04
<b>Left</b>	4.18±0.07	3.85±0.03	3.43±0.02	2.75±0.04
<b>P value</b>	0.27	0.09	0.78	0.0005*

Values are expressed as Mean ± SEM, n = 170, \* - significant, \*P < 0.05.

**Table 3: Distance between Henle's Spine to Stylomastoid and Jugular Foramen**

Mean Distance	Stylomastoid Foramen Mean ± SEM (cm)	Jugular Foramen Mean ± SEM (cm)	
		Anterior	Posterior
<b>Right</b>	2.9±0.03	3.71±0.03	3.77±0.03
<b>Left</b>	2.1±0.02	3.64±0.04	3.04±0.03
<b>P value</b>	0.005*	0.16	0.002*

Values are expressed as Mean ± SEM, n = 170, \* - significant, \*P < 0.05.

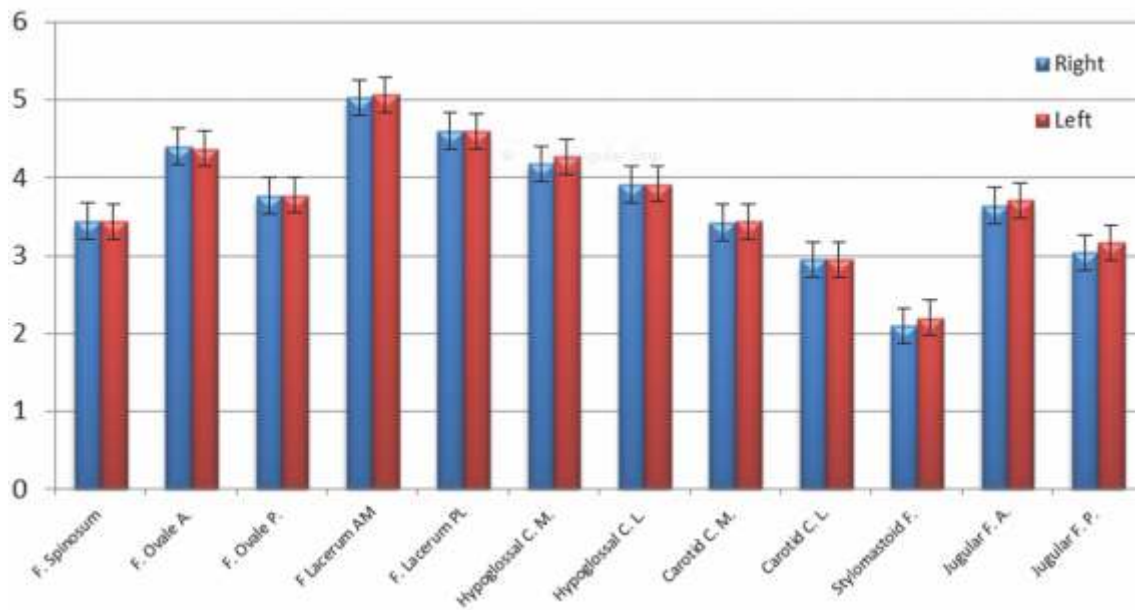


Fig. 5: Distance from Henle's Spine to Various Anatomical Landmarks

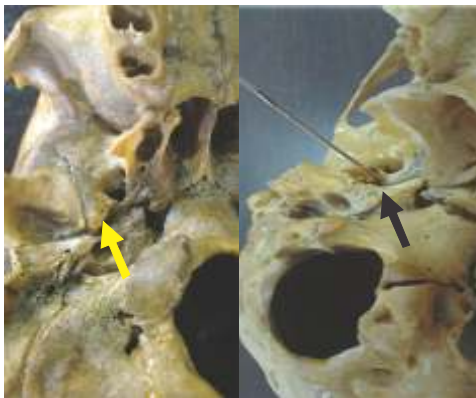

Fig. 6: Absence of Foramen Spinosum, Double Foramen Spinosum

**Discussion:**

The study deals with the HS as an easily identifiable and useful surgical landmark on the skull and its distance from various anatomical structures. Ulug *et al.* recognized HS as a guide to the lateral wall of the mastoid antrum [7]. As the parapetrosal triangle includes the region around

the clivus and provides valuable guidance to important structures at the skull base namely petrosal part of the internal carotid artery, jugular bulb, cranial nerves, greater and lesser petrosal nerves, intracranial entrance point of middle meningeal artery [8]. The measurements, lines and the triangle is well applicable at the internal surface as well as external surface of skull base. The spinopterygoid line, bispinal line and parapetrosal triangle are useful guides during infratemporal fossa approach, anterior and posterior approaches to middle cranial fossa. [8] Similar measurements were done by Ulug *et al.* (2005) [7], Ray *et al.*, (2011) [8], Yogitha *et al.*,(2016) [9] in which the HS was considered as a major landmark and the mean range results of both sides were compared with the present study mean range (Table 4).

The distance of foramen spinosum from HS was found to be with in the same range from all the

**Table 4: Comparative Values Dry Skulls between Previous and Present Study**

Surgical landmarks on the skull base	Ulug <i>et al.</i> , (2005) [7] (mm)	Ray <i>et al.</i> , (2011) [8] (mm)	Yogitha <i>et al.</i> , (2016) [9] (mm)	Present study (2017) (mm)
Foramen Spinosum	33.6	34.2	-	34.4
Anterior margin of Foramen Ovale	44.7	45.7	42.57	43.7
Posterior margin of Foramen Ovale	37.9	38.2	35.96	37.8
Anterior margin of Jugular Foramen	-	-	34.08	37.0
Posterior margin of Jugular Foramen	23.4	32.0	22.82	37.7
Anteromedial margin of Foramen Lacerum	62.6	51.7	-	50.7
Posterolateral margin of Foramen Lacerum	47.0	46.1	-	46.0
Medial margin of Hypoglossal Canal	37.9	40.6	-	42.7
Lateral margin of Hypoglossal Canal	-	-	-	39.2
Stylomastoid Foramen	16.5	18.7	-	22
Medial margin of Carotid Canal	34.5	35.9	32.27	34.4
Lateral margin of Carotid Canal	28.7	27.6	26.68	29.5

previous study when compared to present study. The distance from HS to anterior and posterior margin of foramen ovale showed same measurement as that of Ulug *et al.*, when compared with other studies the distance varied slightly may be due to gender, racial difference with variability in methodology. Distance from HS to anterior and posterior margin of jugular foramen showed vast difference (5 to 8 mm) from the previous study (Table 4) and was found to be significant for posterior margin of jugular foramen when compared between both the sides (Table 3). The area around the jugular foramen of the cranial base is irregular with the foramen being

at the junction of two bones, the occipital and petrous part of the temporal bone transmitting important neurovascular structures which needs more attention of the surgeon during skull base surgery. Anteromedial margin and posteromedial margin of foramen lacerum from HS was found to be less when compared to earlier studies (Table 4) [7,8]. Distance of medial margin of hypoglossal canal from HS was more in the present study with a difference of 2 to 5 mm when compared with other studies [7,8]. Distance from HS to lateral margin of hypoglossal canal was 39.2 mm which was reported only in the present study (Table 4). HS to Stylomastoid foramen distance was more

with a difference of 4 to 5 mm when compared with the studies done by Ulug *et al.* and Biswabina *et al.* [7,8] and was found to be statistically significant when compared between the sides in the present study (Table 3). The distance from medial and lateral margin of carotid canal were within the same range of other studies and does not show much difference (Table 4) [7-9]. When compared between right and left side the lateral margin of carotid canal distance from HS was statistically significant (Table 2). The distance variation among the previous and present study may be due to gender difference, racial difference with variability in methodology.

#### Variations of Foramina:

The prevalence of foramen spinosum in the human skulls in various past studies varies from 98.5% (Lang *et al.*) to 99.6% (Lindblom *et al.*) (Singh *et al.*) [10-12]. In this study, it was 99% (Fig. 6), which is comparable (Somesh *et al.*, 98.8%) [13]. It is associated with altered course of the middle meningeal artery, where it arises from the

ophthalmic artery and enters the middle cranial fossa through the superior orbital fissure (Lindblom *et al.*) or through Foramen Ovale [11]. In one of the skull foramen spinosum was absent (Fig. 6).

#### Conclusion:

Parapetrosal triangle provides valuable guidance to important structures at the skull base. Spinopterygoid line, bispinal line and parapetrosal triangle are useful guides during infratemporal fossa approach, anterior and posterior approaches to middle cranial fossa. HS spine (85%) can be used as a reliable anatomical landmark for approaching various foramina during skull base surgeries when other land mark fails. Foramen spinosum, ovale, lacerum, carotid and hypoglossal canal, stylomastoid and jugular foramen appears to have a constant relationship to HS, hence, it can be used as a reliable surface landmark in skull base surgeries. However, the possibility of side difference should be kept in mind prior to surgeries.

#### References

1. Shoma NM, Samya RN, Pensak ML. Radiographic assessment and surgical implications of arcuate eminence pneumatization. *ORL J Otorhinolaryngol Relat Spec* 2016; 78(1):9-15.
2. Demir MT, Kopuz C, Pirzirenli MEA. The localization of the asterion according to the anatomical landmarks of posterior cranial fossa in newborns: clinical implications. *Int J Morphol* 2015; 33(2): 685-94.
3. Adoga SA, Mann ND, Benjamim T, Umar BM, Nwaorgu GO. Temporal bone dissection skill: a necessity for life otologic surgeries? *Indian J Otol* 2011; 17(2): 71-4.
4. Hashemi J, Rajati M, Rezayani L, Bahadori A. Temporal bone measurement; a comparison between rendered spiral CT and surgery. *Iran J Radiol* 2014; 11(3): e9400.
5. Jackson RCC. Morphologic and roentgenologic aspects of the temporal bone study of 536 bones with special reference to pneumatization. *Arch Otolaryngol* 1938; 28(5):748-67.
6. Williams PL, Bannister LH, Berry MM, Collins P, Dyson M, Dussek JE, Ferguson MWJ (eds), Gray's Anatomy: The Anatomical Basis of Medicine And Surgery, 38<sup>th</sup> edition, Churchill Livingstone, London, 1995; 561.
7. Ulug T, Ozturk A, Sahinoglu K. A multipurpose landmark for skull-base surgery: Henle's spine. *J Laryngol Otol* 2005, 119(11): 856-61.
8. Ray B, Rajagopal KV, Rajesh T, Gayathri BM, D'Souza AS, Swarnashri JV, *et al.* Morphometry and CT measurements of useful bony landmarks of skull base. *Rom J Morphol Embryo* 2011; 52(3): 873-877

- 
9. Yogitha Ravindranath, Bailur J, Kishan V, *et al.* Anatomic study of localization of foramen ovale, carotid canal, jugular foramen using Henle's spine as surface landmark in South Indian adult skulls. *J Evolution Med Dent Sci* 2016; 5(53): 3569-72.
  10. Lang J, Maier R, Schafhauser O. Postnatal enlargement of the foramina rotundum, ovale et spinosum and their topographical changes. *Anat Anz* 1984; 156(5): 51-87.
  11. Lindblom K. Aroentgenographic study of the vascular tumors and arteriovenous aneurysms. *Acta Radiol* 1936; 30: 1-146.
  12. Singh B and Singh B. Study of middle cranial foramina GMCH, Chandigarh. *J Anat Soc India* 2001; 50(1): 69-98.
  13. SomeshMS, Murlimanju BV, Ashwin Krishnamurthy, Sridevi HB. An anatomical study of foramen spinosum in South Indian dry skulls with its emphasis on morphology and morphometry. *Int J Anat Res* 2015; 3(2): 1034-38.
- 

*\*Author for Correspondence: Dr. B. Senthil Kumar, Department of Anatomy,  
Vinayaka Mission's Kirupananda Variyar Medical College and Hospital, Salem – 636308, Tamil Nadu  
Email: skdrchinu88@gmail.com Cell: 09894398677*