

## CASE REPORT

**Idiopathic Calcinosis Cutis over Back***Tanveer Shaikh<sup>1</sup>, Siddharth P. Dubhashi<sup>1\*</sup>**<sup>1</sup>Department of General Surgery, MGM Medical College and Hospital, Navi Mumbai-(Maharashtra)  
India***Abstract:**

Calcinosis Cutis is characterized by the deposition of calcium salts in the skin and subcutaneous tissue. Idiopathic Calcinosis Cutis is a rare condition and hence is usually a diagnosis of exclusion. Idiopathic Calcinosis Cutis occurs in the absence of known trauma, inciting agent or metabolic defect. This is a case report of an adult female presenting with Idiopathic Calcinosis Cutis over the back. The exact mechanism of occurrence of this condition is not known. Patients are usually managed with pharmacotherapy, surgery being reserved for those with pain, recurrent infection and impaired function. The lesions are known to recur and a periodic follow-up of these patients is essential.

**Keywords:** Calcification, Recurrence, Surgery

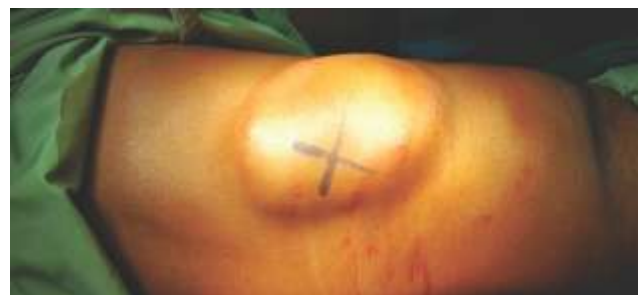**Introduction:**

Calcinosis Cutis (CC) is characterized by the deposition of calcium salts in the skin and subcutaneous tissue. Based on etiology, CC is classified into: dystrophic calcification (localized/wide spread tissue damage), metastatic calcification (abnormal calcium and phosphate metabolism), idiopathic calcification and iatrogenic calcification [1]. Idiopathic Calcinosis Cutis (ICC) is a rare condition and hence is usually a diagnosis of exclusion [2]. This is a case report of an adult female presenting with Idiopathic Calcinosis Cutis.

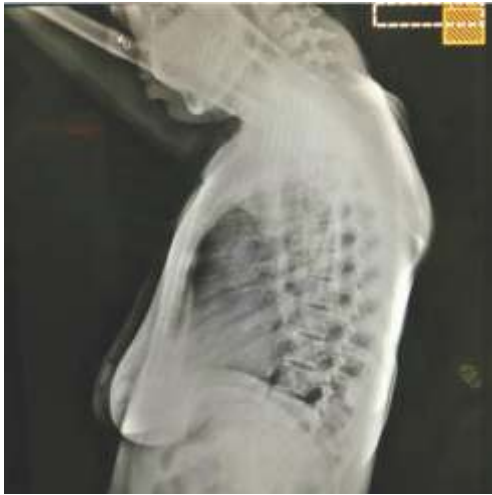**Case Report:**

A 40-year-old housewife presented to the surgical Out-patients Department with a progressively increasing swelling on the back since birth and associated pain for 5 months. There was no history

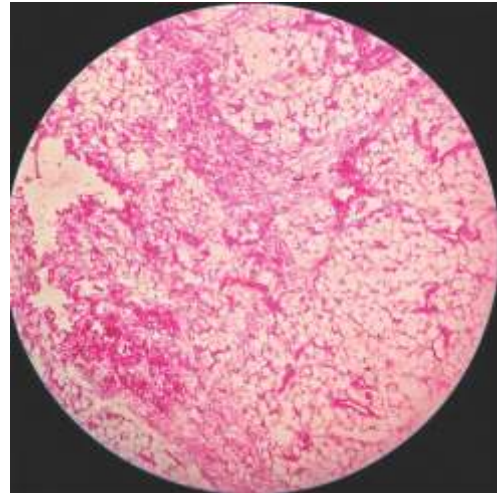
of similar lesions over the breast, genitalia or any other site. There was no history of trauma or pathologic lesions. No history of fever or loss of weight or appetite was present. On examination, there was single oval, smooth, well defined edge, non fluctuating, non trans-illuminant, nonpulsatile, irreducible, mobile, tender swelling with variegated consistency on the back near right scapular region measuring 8x5 cm (Fig. 1). There were no signs of inflammation. Blood Tests revealed serum calcium of 9.39 mg/dL (8.9-10.3), serum phosphorus of 3.41 mg/dL (2.5-4.5), urinary calcium of 1.18mg/dL and normal parathyroid assay. X-ray (Fig. 2) and Ultrasonography of swelling demonstrated calcinosis. FNAC revealed the accumulation of calcium salts in the dermis. The swelling was excised in toto (Fig. 3) and histopathology report revealed tissue comprising of fibrocollagenous tissue admixed with mature adipocytes, congested blood vessels and large area of calcification features consistent with CC (Fig. 4). The patient was administered antibiotics for 10 days and advised periodic follow up.



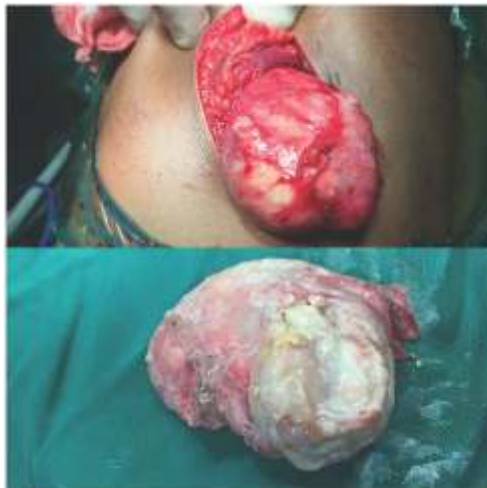**Fig. 1: Swelling over Back**



**Fig. 2: X-Ray showing Calcified Nodules over Scapular Region**



**Fig. 4: HPE Findings**

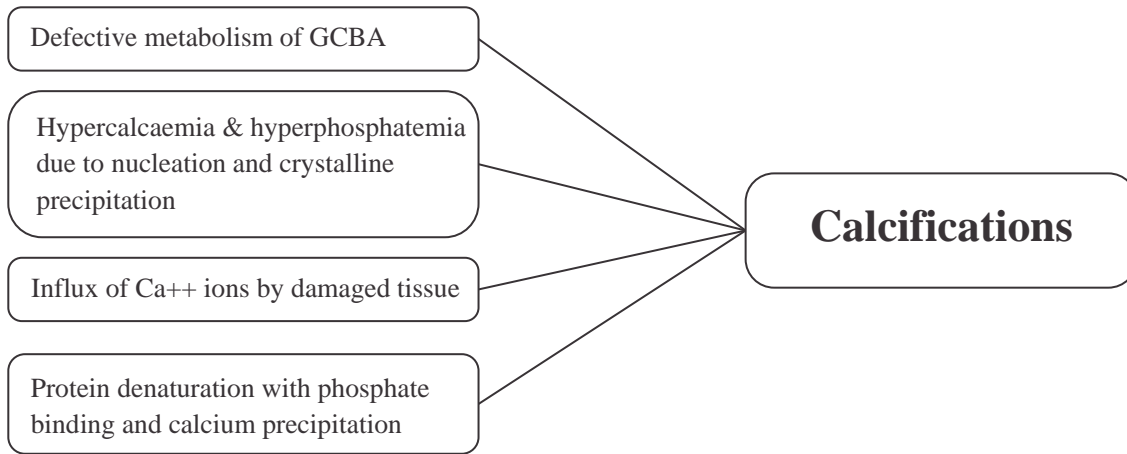


**Fig. 3: Excised Specimen**

**Discussion:**

CC was initially described in 1855 by Virchow [3]. Dystrophic variety is the commonest and is associated with Calcinosis, Raynaud's phenomenon, Esophageal dysmotility, Sclerodactyly, Telangiectasia (CREST) Syndrome and dermatomyositis [4]. ICC occurs in the absence of known trauma, inciting agent or metabolic defect. It can be classified as sub-epidermal calcified nodule, tumoral calcinosis, calcinosis cutis

circumscripta, calcinosis universalis, scrotal calcinosis and milia-like calcinosis. Tumoral Calcinosis manifests as masses around joints in otherwise healthy adolescents and sub-epidermal nodules occur on head and extremities in children [5, 6]. The disease is usually seen over vulva, scrotum, penis and breast [7]. The histopathological examination usually shows calcium deposits in the dermis, with or without foreign-body giant cell reaction. Blood vessels may also contain calcium deposits [5]. Our case did not have any history of trauma or parenteral calcium therapy, had all blood investigations within normal limits and histopathology revealed areas of calcification in the dermis. The exact mechanism of occurrence of this condition is not known. Various treatment options have been outlined for ICC. Medical treatment includes bisphosphonates, warfarin, probenecid, colchicine, intra-lesional corticosteroids, magnesium or aluminum antacids and diltiazem [10, 11]. Surgical excision is usually done in patients presenting with painful lesions, as in our case. Recurrent infections, ulceration and impaired function are also indications for surgical



Possible Mechanism [8, 9]

intervention [5]. However, recurrence rates are reported to be high [12].

#### Conclusion:

ICC is a rare occurrence and usually a diagnosis of exclusion. Medical treatment is usually prolonged

and offers limited benefits. Surgery is done in cases with pain, recurrent infections, ulceration and functional impairment. A periodic follow-up of patients is warranted to check for recurrence.

#### References

1. Cohen PR, Tschen JA. Idiopathic Calcinosis Cutis of the Penis. *J Clin Aesthet Dermatol* 2012; 5: 23-30.
2. Aksoy HM, Ozdemir R, Karaaslan O, et al. Incidental idiopathic calcinosis cutis in a rhytidectomy patient. *Dermatol Surg* 2004; 30: 1145-1147.
3. Reiter N, El-Shabrawi L, Leinweber B, et al. Calcinosis cutis: part I. Diagnostic pathway. *J Am Acad Dermatol* 2011; 65: 1-12.
4. Larralde M, Giachetti A, Caceres MR, et al. Calcinosis cutis following trauma. *Pediatr Dermatol* 2005; 22: 227-229.
5. Jatana SK, Negi V, Das S. A case of idiopathic calcinosis cutis. *MJAFI* 2012; 68(4):383-385.
6. Walsh JS, Fairley JA. Calcifying disorders of the skin. *J Am Acad Dermatol* 1995; 33: 693-706.
7. Özçelik B, Serin IS, Basbug M, et al. Idiopathic calcinosis cutis of the vulva in an elderly woman: a case report. *J Reprod Med* 2002; 47: 597-599.
8. Lanka P, Lanka LR, Ethirajan N, Krishnaswamy B, Manohar U. Idiopathic Calcinosis Cutis. *Indian J Dermatol* 2009; 54(4):388-389.
9. Tristano AG, Villarroel JL, Rodriguez MA, Milan A. Calcinosis Cutis universalis in a patient with systemic lupus erythromatosus. *Clin Rheumatol* 2006; 25(1): 70-74.
10. Wang Wen-Jen, Lo Wen-Lin, Wong Chu-Kwan. Calcinosis Cutis in juvenile dermatomyositis: remarkable response to aluminum hydroxide therapy. *Arch Dermatol* 1988; 124: 1721-1722.
11. Rodan GA. Mechanisms of action of bisphosphonates. *Annu Rev Pharmacol Toxicol* 1998; 38: 375-388.
12. Prabhu R, Sarma YS, Phillip K, Sadhu S. Diffuse Idiopathic Calcinosis Cutis in an Adult: A Rare Case. *Eurasian J Med* 2014; 46(2):131-134.

\* Author for Correspondence: Prof. Dr. Siddharth P. Dubhashi, A2/103, Shivranjan towers, Someshwarwadi, Pashan, Pune-411008 Email:spdubhashi@gmail.com Cell: 9881624422