

CASE REPORT

Delayed Sino-Orbital Aspergillosis Following Facial Injury: A Case Report

Vinayak Raje¹, Ganesh Vihapure², Pandurang Barve¹, Devdutta Patil¹, Meghana Chougule³,
Trishant Chotai¹

¹Department of Neurosurgery, ²Department of ENT, Krishna Institute of Medical Sciences Deemed University, Karad-415110, ³Consulting Pathologist, Shanti Pathology Laboratory Karad-415110 India

Abstract:

Aspergillosis of face affects the nose and eyes mainly. The invasive and in particular, the fulminant forms are associated with high mortality. We report a case of sino-orbital aspergillosis in a known case of diabetes mellitus. The Patient underwent surgery for debridement of right maxillary sinus through transnasal approach. Successful treatment of aspergillosis requires prompt diagnosis and institution of therapy, because delay or non aggressive therapy can result in spread in infection and lethal consequences.

Keywords: Fungal infection, Paranasal Sinuses, Invasive Aspergillosis

Introduction:

Aspergillosis belongs to the category of systemic mycoses. Although pulmonary invasive aspergillosis is most common [1], other anatomical sites have been described as rare including sinuses, cerebral meninges, myocardium, thyroid, bone. Invasive and in particular, the fulminant forms are associated with high mortality. Invasive form primarily affects paranasal sinuses and nose [2]. Orbital involvement worsens the prognosis because of ready availability of pathways for further intracranial spread, such as superior orbital fissure, optic canal that directly open into the middle cranial fossa. High degree of suspicion for the diagnosis and early aggressive therapy are suggested to decrease morbidity and mortality.

We report a case of post trauma sino-orbital aspergillosis in a known case of diabetes mellitus following trauma.

Case Report:

A 45 year male patient reported with complaint of right orbital swelling due to trauma. He later developed tenderness and swelling in the right infra orbital region. CT orbit was suggestive of ill defined soft tissue density lesion noted in the right maxillary sinus, involving the floor of orbit displacing inferior and medial rectus with thinning and erosion of the floor and medial wall of orbit extending to nasal cavity. CT scan was suggestive of displaced fracture (blow out) of floor of right orbit and medial wall. Large collection was seen in floor of right orbit, causing compression on right eye and extra ocular muscles of right eye. Displaced fracture of right maxillary sinus with haemosinus shown in Fig.1. Right endonasal maxillary and orbital decompression followed by diagnostic transnasal endoscopy was done. Histopathology report suggested aspergillosis. Mucopurulent discharge sent for culture and sensitivity and was sensitive to Amphotericin B. The culture report suggested *Aspergillus* species. Intravenous therapy of Amphotericin B was started and patient improved symptomatically.

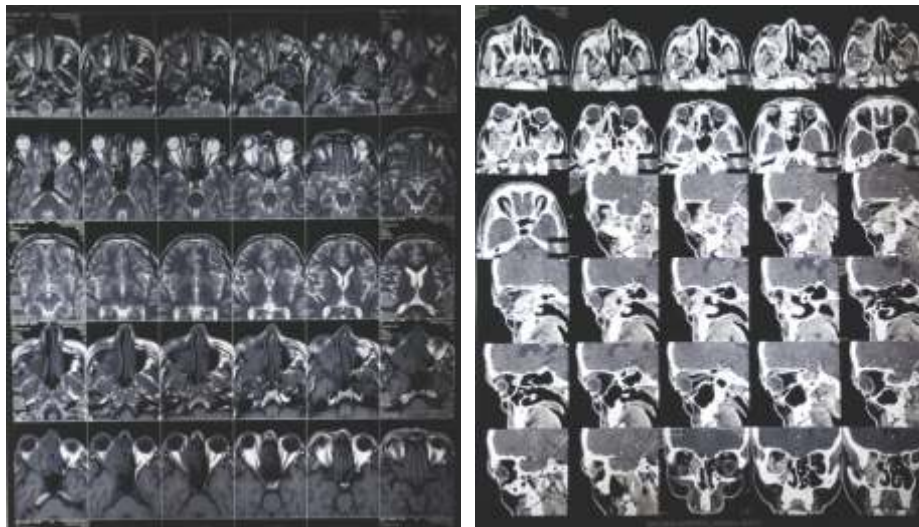


Fig. 1: Pre Operative CT Scan Showing Hypodense in the Right Maxillary Sinus

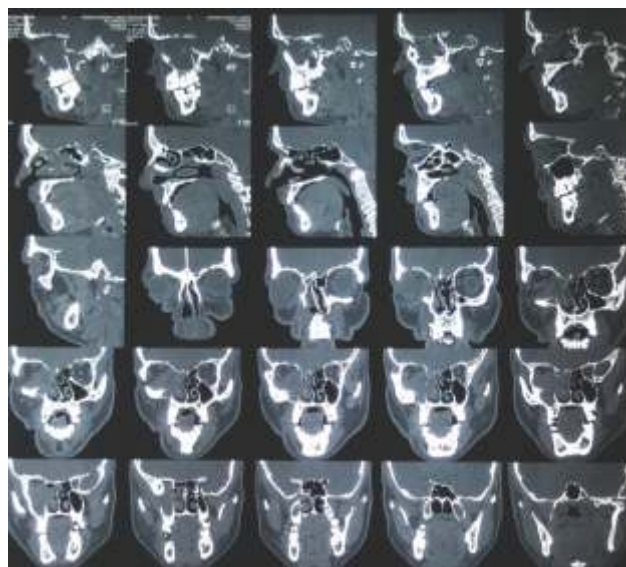


Fig. 2: Pre Operative CT Scan Showing Haziness in the Right Maxillary Sinus

Discussion:

Aspergillus species are ubiquitous, commonly found in soil and decaying vegetation. Spores are typically inhaled or ingested without consequence in the normal host and exposure to this fungus is frequent, yet disease due to tissue invasion is uncommon in the host. Portals of entry for Aspergillus include the respiratory tract, damaged

skin or other operative wound, the cornea and the ear. An intact immune system can prevent the disease in the healthy individual and there may be mechanism by which fungi affect the sinus mucosa in susceptible individual. The overall fatality rate of 58 to 67% demonstrate that invasive aspergillosis of any type remains a highly

lethal opportunistic infection despite the availability of newer anti-fungal therapy and improved management of underlying diseases [3]. Aspergillosis of head and neck region, primarily affects nasal cavity and paranasal sinuses [2]. Aspergillus as a pathogen cannot actively penetrate undamaged and intact mucous membrane or skin as it lacks keratolytic enzymes. Aspergillosis is classified into invasive (acute fulminant, chronic invasive, granulomatous invasive) and non-invasive (fungus ball and allergic fungal rhinosinusitis) type [1, 4]. Other predisposing factors include HIV infection, diabetes mellitus, trauma, excessive environmental exposure and possibly advanced age. Orbital involvement in such patients is known to cause loss of vision. Orbital involvement occurs by contiguous spread of the diseases from paranasal sinuses, expansion or bone erosion due to pressure effect of fungal tissue invasion. The extension of the sinus tissue infection is either through osseous structure like the lamina papyracea or through haematogenous spread by valveless venous plexus to orbit, brain or skin. The rapid progression of this disease with

orbital involvement and severe unilateral headache raised suspicion of sino-orbital aspergillosis.

Amphotericin B is considered the gold standard based on extensive experience [5]. Therapy is often prolonged and can be complicated by adverse effects, the most serious of which is renal dysfunction. Newer formulations, including lipid complex and liposomal forms, have been developed to decrease the toxicity of amphotericin B and indeed appear to be less toxic and more efficacious. Of the azole class, itraconazole and voriconazole are the most promising and are safer and easier to administer than Amphotericin [6].

Conclusion:

Unusual infections like primary aspergillosis are difficult to diagnose unless there is high index of suspicion. Localized invasive sino-orbital aspergillosis was thought to be a rare disease following trauma but we have reported this case. Awareness of this disease with its characteristic symptoms, signs, and imaging features may lead to earlier diagnosis and treatment, and improved outcome.

References

- Walsh TJ, Finberg RW, Arndt C. Liposomal amphotericin B for empirical therapy in patients with persistent fever and neutropenia. *N Engl J Med* 1999; 340:764–71.
- Streppel M, Bachmann G, Damm M, et al. Successful treatment of an invasive aspergillosis of the skull base and paranasal sinuses with liposomal amphotericin B and itraconazole. *Ann Otol Rhinol Laryngol* 1999; 108:205–7.
- Bradley SF, McGuire NM, Kauffman CA. Sino-orbital and cerebral aspergillosis: cure with medical therapy. *Mykosen* 1987; 30:379–85.
- Lowe J, Bradley J. Cerebral and orbital aspergillus infection due to invasive aspergillosis of ethmoid sinus. *J Clin Pathol* 1986; 39:774–8.
- Yu VL, Wagner GE, Shadomy S. Sino-orbital aspergillosis treated with combination antifungal therapy. Successful therapy after failure with amphotericin B and surgery. *JAMA* 1980; 244:814–15.
- Gabelmann A, Klein S, Kern W, Kruger S, Brambs HJ, RieberBrambs A, Pauls S. Relevant imaging findings of cerebral aspergillosis on MRI: a retrospective case-based study in immunocompromised patients. *Eur J Neurol* 2007; 14:548–55.

*Author for Correspondence: Dr. Pandurang Barve, Department of Neurosurgery, KIMSUDU, Karad
Email: pandurangexams@gmail.com Cell: 9765224119