

CASE REPORT**Management of Mixed Hemangiolympangioma with Kasabach-Merritt Syndrome
- A Case Report and Review of Literature**

D. Srinivasan^{1}, SreeRamulu P. N.¹, Sangamesh¹, Harish Kumar. G.¹, Prashanth K. Dhannur¹*

¹Department of Surgery, Sri Devaraj Urs Academy of Higher Education and Research, Kolar - 563101, (Karnataka), India.

Abstract:

A young boy of 5 years presented with in our OPD with the globular swelling over the dorsum of right hand with clinical features of vascular haemangioma present from birth, gradually growing with the age and attained the size of 6 x 5 cms never had any bleeding diatheses, platelet count was 80,000 / cumm. Before the platelet could dip surgery was contemplated and excision done. Haemangiomas are vascular lesions resulting from abnormal proliferation of blood vessels. They are the most common pediatric neoplasms. Kasabach-Merritt syndrome is a rare type of vascular lesion with peculiar characteristics. The diagnosis is based upon three basic findings; enlarging hemangioma, thrombocytopenia and consumption coagulopathy. The mortality is nearly 30%. Hemangiomas can be associated with genetic disorder thus chromosome tests (to exclude certain genetic syndromes) is advocated.

Keywords: Congenital, Haemangiomas, Kasabach-Merritt Syndrome, Vascular mal-formation

Case Report:

A 5 year old boy was admitted to the surgery department for the management of swelling on the dorsum of right hand from birth. At birth a bluish birth mark 0.5 x 0.5 cms was noted and grew to the present status as the child grew attaining the present size of 6 x 5 cms 9 (Fig.1), and evolved into a swelling. He was the first child of consanguineous parents, born in a private hospital following uncomplicated pregnancy and delivery, presented to the surgical outpatient department.

with swelling on the dorsum of right hand.

The clinical findings and imagining studies followed by laboratory investigations strongly suggested the diagnosis of Kasabach-Merritt Syndrome (KMS). The platelet count was 80,000 /cu.mm. After a trial of corticosteroids when the platelet count never improved even after one week and started dipping, an early surgery was planned. The mixed cystic lesion with upper half of the swelling being firm and lower half was cystic and compressibility being positive was excised which was infiltrating into skeletal muscles.

Histopathological examination of swelling revealed Mixed Hemangio-lymphangioma with infiltration into skeletal muscles.

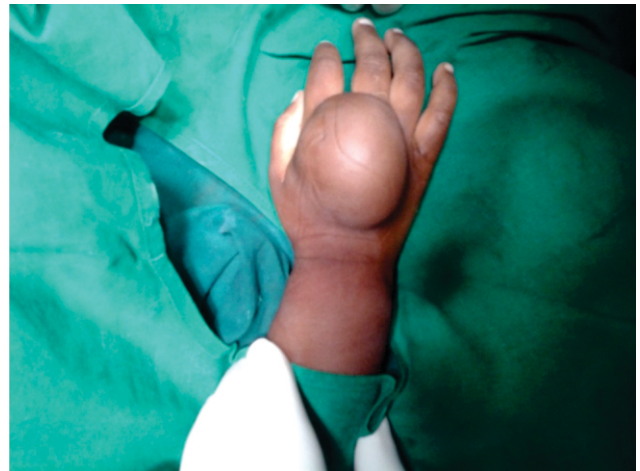

Fig.1: Clinical Photograph of Swelling

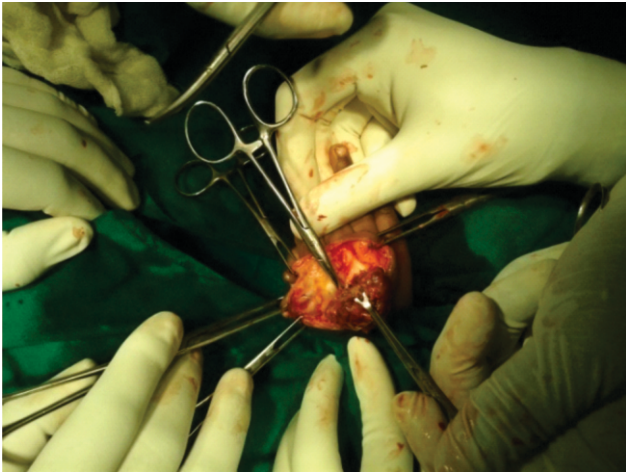


Fig.2: Hemangio-Lymphangioma Being Excised

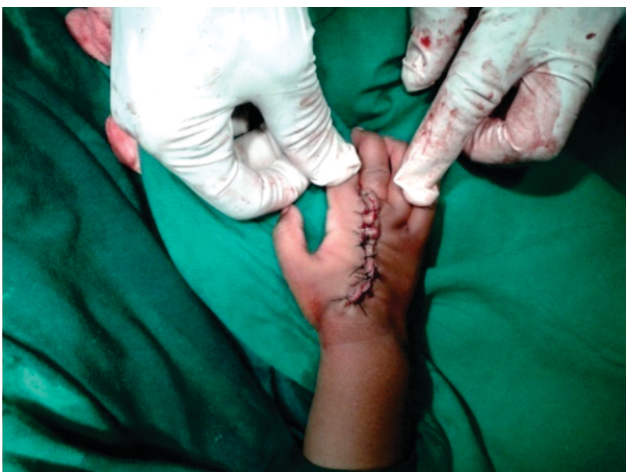

Fig.3: Excess Skin was Excised and Sutured

Discussion:

Haemangiomas are vascular lesions resulting from abnormal proliferation of blood vessels. They are the most common pediatric neoplasm. They have a special importance in clinical practice because of their distinct properties and behaviour. Some hemangiomas are very small and hardly visible while others are large producing significant disfigurement.

The management of these lesions not only depends upon their size and site but also on several other distinct features as for Kasabach-Merritt

syndrome, Klippel-Trenaunay-Weber syndrome, Sturge-Weber syndrome, Rendu-Osler-Weber syndrome and von Hippel-Lindau disease [1].

Kasabach-Merritt syndrome is a rare type of vascular lesion with peculiar characteristics. Thus Chromosome tests are carried out to exclude certain genetic syndromes. The diagnosis is based upon three basic findings; enlarging haemangioma, thrombocytopenia and consumption coagulopathy. The thrombocytopenia and consumption coagulopathy is known as Kasabach-Merritt phenomenon [1]. It is argued that exposure of subendothelial elements or abnormal endothelium within the haemangioma results in aggregation and activation of platelets with a secondary consumption of clotting factors [2]. If untreated, Kasabach-Merritt syndrome can be life threatening with a high mortality due to consumptive coagulopathy [DIC] Cavernous hemangiomas are the most common benign tumours of the liver. They can reach enormous sizes and cause various complications. Kasabach-Merritt syndrome is a rare but serious complication characterized by consumptive coagulopathy caused by the hemangioma; mortality rate ranges between 10 and 37%. More than 80% of cases occur within the first year of life

The present report describes a patient with Kasabach-Merritt syndrome. The clinical presentation of the case and outcome of selected treatment modalities are discussed in the light of previous studies done in connection with this subject.

No single pharmacologic therapy has been proved most effective in patients with KMS. Agents that have been tried (most of them not specifically FDA-approved for this application), with varying success, include the Corticosteroids (most commonly used), Interferon alfa, Aminocaproic acid, Aspirin, Dipyridamole, Ticlopidine, Pentoxifylline, Cryoprecipitate, Heparin, Vincristine,

Cyclophosphamide, Actinomycin D, Propranolol.

- Non pharmacologic treatment modalities include the following:
- Surgical resection (when lesions are not too large or surgically inaccessible) - Wide local excision is recommended but may be difficult; amputation may be necessary for intractable lesions involving a limb
- Interventional radiologic procedures (when surgical treatment is not feasible)
- Intermittent pneumatic compression (most useful for a vascular lesion located on an extremity)
- Radiation therapy (now largely abandoned because of long-term adverse effects)

Conclusion:

A major mainstay of the treatment of Kasabach-Merritt syndrome is surgical excision. This

approach is recommended for single cutaneous lesions or multiple lesions in the spleen (splenectomy) or liver (wedge resection / hepatectomy) [2-4]. This is the only treatment that provides cure in significant number of cases. However, before each surgical intervention the patient must be stabilized: surgical excision and identifying the feeding vessel and ligating the same in this case the feeding vessel was from dorsal palmar vessels may be the best management in selected cases of Kasabach-Merritt syndrome.

Acknowledgement:

We are thankful to Dr. Y. C. Manjunath, Radiologist and C. S. B. R. Prasad, Associate Professor in Pathology, Sri Devaraj Urs Academy of Higher Education and Research for the help to diagnosis of this case.

References:

1. Abbas AAH, Raddadi AA, Chedid FD. Haemangiomas: a review of the clinical presentations and treatment. *Middle East Paediatrics* 2003; 8(2):52-58.
2. Hall GW. Kasabach-Merritt syndrome: pathogenesis and management. *Br J Haematol* 2001; 112:851-862.
3. Drolet BA, Scott LA, Esterly NB, Gosain AK. Early surgical intervention in a patient with Kasabach-Merritt phenomenon. *J Pediatr* 2001; 138(5):756-758.
4. Pasqual E, Bacchetti S, Gasparini D, Sponza M, Cagol PP. Embolisation of arteriovenous intrahepatic fistulas associated with diffuse haemangiomatosis of the liver. Report of a case in an adult and review of the literature. *Chir Ital* 2007; 59(5):701-705.

***Author For Correspondence:** Dr. Srinivasan D., Assistant Professor, Sri Devaraj Urs Academy of Higher Education and Research Kolar - 563101 (Karnataka), India.
Cell: 8105576075, Email: drsrinivasandorai@gmail.com