
CASE REPORT**Lepromatous Leprosy of Prepuce- A Case Report**

Sachin A. Badge^{1*}, Alka V Gosavi¹, Nayan A. Ramteerthkar¹, Kalpana R. Sulhyan¹

¹Department of Pathology, Government Medical College, Miraj – 416410 (Maharashtra), India

Abstract:

Leprosy is commonly seen over cooler parts of the body and very rarely found over external genitalia because of their warm temperature. We report a case of lepromatous leprosy of prepuce in a 79 years old male who presented with phimosis. Local examination revealed a nodule over prepuce and the clinical diagnosis was carcinoma of penis. This case highlights that leprosy should be kept in mind in the differential diagnosis of penile lesions.

Key words: Leprosy, prepuce

Introduction:

Hansen's disease is caused by *Mycobacterium leprae*, which has a distinct predilection for the cooler parts of the body [1]. So it is commonly found over face, knees, elbows, dorsal aspects of the extremities, trunk and gluteal region [2]. It is rarely found over scalp, palms and soles, genitalia, groins, axillae, eyelids, transverse band of skin over lumbosacral area, and midline of back and perineum because of their warm temperature and are called immune zones [3]. Although leprosy is prevalent in India, only few cases of genital involvement of leprosy have been reported so far [4-7].

Case report:

A 79 years old male presented with phimosis since 5 months. Local examination showed a nodular lesion measuring 2x1 cm over prepuce. There were multiple small nodular lesions over

both the hands. Bilateral inguinal lymph nodes were palpable. Clinical diagnosis was carcinoma of penis. Biopsy of the prepuce nodule was done. Routine investigations like hemogram, urine examination and chest x-ray were within normal limits. VDRL and ELISA for HIV were also negative. Histopathological examination of the prepuce nodule showed many periadnexal, perivascular and perineural granulomas in the dermis. (Fig. 1)

These granulomas were composed of mainly foamy histiocytes forming globi admixed with few lymphocytes. (Fig. 2)

A diagnosis of lepromatous leprosy was suspected. 5% AFB staining was done and detailed clinical history was asked. 5% AFB stain showed many Acid Fast Bacilli. At the same time history was obtained, the patient was a known case of lepromatous leprosy and he was on multibacillary multidrug therapy since last 6 months.

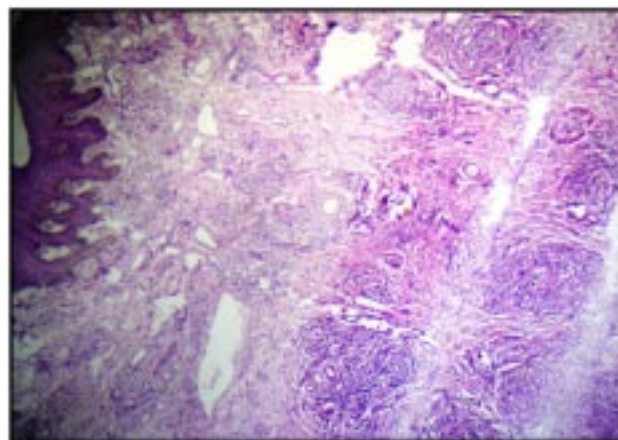


Fig. 1: Periadnexal, perivascular and perineural granulomas in the dermis (4X, H and E)

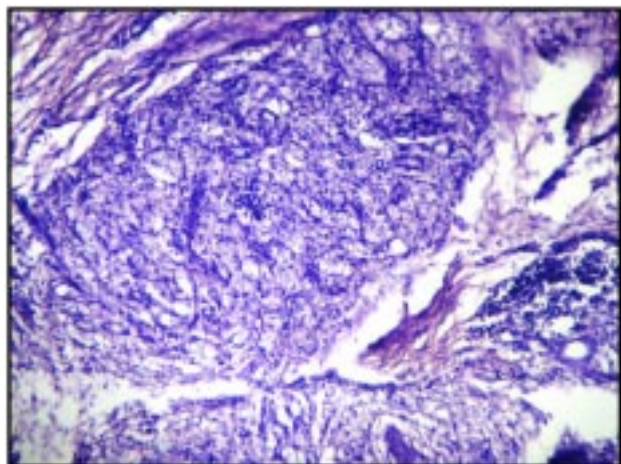


Fig. 2: Granulomas composed of mainly foamy histiocytes forming globi and few lymphocytes (40X, H and E)

Discussion:

Review of literature shows that involvement of male genitalia by leprosy is rare [5- 7]. Arora et al. (1989) and kumar et al. (2001) reported involvement of genital lesions in 2.9% and 6.6% of leprosy patients respectively [8, 9]. All types of leprosy lesions can involve male genitalia however lepromatous leprosy lesions are more commonly seen than tuberculoid leprosy lesions. Most of the patients belonged to borderline and borderline lepromatous group respectively. Scrotum is the commonest site of involvement while prepuce is very rarely in-

Table 1: Literature review

AUTHOR	TT	BT	BB	BL	LL	SITE
Arora et al (1989)			8	2	3	Scrotum-9 Scrotum and penis- 3 Scrotum, prepuce and glance penis-1
Dixit et al (1990)	1					Scrotum and penile skin
G kumar Krishna (1992)	1					Scrotum
Maru et al (1996)				1		Prepuce
Ghorpade A (2000)	1					Shaft of penis
Bhushan kumar et al (2001)		4		19	8	Scrotum and penis-19 Scrotum-5 Penis-7
IN Shaw (2002)		1				Prepuce
Ghorpade A(2003)		1				Penile shaft with prepuce
Ghorpade A (2004)	2					Both on glans penis
Bikas ranjekar (2005)	1					Shaft of penis
Mukopathyay (2005)					1	Penile shaft
Kowit (2009)		2				Scrotum-1, prepuce-1
Basanti devi (2009)		1				Prepuce
Total		15			34	

TT - Tuberculoid leprosy,
BL - Borderline lepromatous leprosy,

BT - Borderline tuberculoid leprosy,
LL - Lepromatous leprosy

BB - Borderline leprosy,

volved. All the cases show involvement of scrotum with or without involvement of shaft of penis, glans and very rarely prepuce. (Table-1) The scrotum is a natural device to keep the testes cool, which could explain the findings of leprosy lesions over the scrotum, whereas lesions over the shaft and prepuce are very rare. The use of occlusive undergarments is likely to increase the temperature of the genital skin which further explains the rarity of leprosy lesions there. However, in India where people are more used to wear loose clothes, it is expected to get more number of genital leprosy cases. Underreporting of these cases is either due to hesitancy of the patient to expose or due to the reluctance of physician to examine the genitalia. Hence thorough genital examination in all leprosy patients should be done. High index of suspicion and thorough clinical and laboratory examination will help to arrive at the proper diagnosis. This case highlights that leprosy should be kept in mind in the differential diagnosis of penile lesions along with malignancies and other sexually transmitted diseases.

References:

1. Anish SA. The relationship between surface temperature and dermal invasion in lepromatous leprosy. *Int J Lepr Other Mycobact Dis* 1971; 39(4):848-51.
2. Indira D, Kaur I, Sharma VK, Das A. Palmoplantar lesions in leprosy. *Indian J Lepr* 1999; 71(2):167-72.
3. Jopling WH, McDougall AC. Handbook of leprosy, 5ed, New Delhi: CBS Publications 1996: 10–49pp.
4. Ghorpade A. Penile shaft lesion in reactional borderline tuberculoid leprosy: a case report. *Indian J Dermatol Venereol Leprol* 2003; 69(6):411-2.
5. Shaw IN, Ebenezer G, Rao GS. Leprosy lesion on the prepuce of the male genitalia: A case report. *Lepr Rev* 2002; 73(3):276-8.
6. Parikh DA, Parikh AC, Ganapati R. Penile and scrotal lesions in leprosy: Case reports. *Lepr Rev* 1989; 60(4): 303-5.
7. Ghorpade A, Ramanan C. Primary penile tuberculoid leprosy. *Indian J Lepr* 2000; 72 (4):499-500.
8. Arora SK, Mukhija RD, Mohan L, Girdhar M. A study of cutaneous lesions on male external genitalia. *Indian J Lepr* 1989; 61(2): 222-4.
9. Kumar B, Kaur I, Rai R, Mandaal SK, Sharma VK. Involvement of male genitalia in leprosy. *Lepr Rev* 2001; 72(1): 70-7.

**Author for Correspondence: Dr. Sachin A. Badge, Department of Pathology, Government Medical College, Miraj – 416410, Cell: 9923039723 Email: Sachin.579@rediffmail.com*