
CASE REPORT**Primary Diffuse Large B-cell Lymphoma of the Uterus Manifesting as a Leiomyoma: A Unique Presentation with Review of Literature**

Sergei Tatishchev¹, Alice Lee², Richard Natural³, Janneth Y. Romero², Rajan Dewar^{4*}

¹Department of Pathology and Laboratory Medicine, University of California, Los Angeles, CA, USA,

²Department of Radiology, ³Department of Pathology, Beth Israel Deaconess Medical Center, Boston, MA, USA, ⁴Department of Pathology, Beth Israel Deaconess Medical Center / Harvard Medical School,

330 Brookline Avenue, Yamins 309, Boston, MA 02215, USA

Abstract:

We report a primary diffuse large B-cell lymphoma of uterine corpus in a 70-years-old woman who presented with symptoms of increased urinary frequency and sense of bloating. Magnetic Resonance Imaging (MRI) findings were suggestive of a degenerating intramural fibroid. Histological examination of tissue samples obtained during hysteroscopy showed diffuse infiltration of fibrous stroma by atypical enlarged mononuclear cells. Immunohistochemical studies were consistent with the diagnosis of diffuse large B-cell lymphoma. Further imaging studies showed no evidence of lymphoma outside the uterus. To our knowledge, this represents the first well-documented case of primary uterine lymphoma presenting as a leiomyoma on imaging studies.

Key Words: Non-Hodgkin lymphoma, uterine corpus, DLBCL, fibroids.

Introduction:

Diffuse large B-cell lymphoma (DLBCL) is the most common type of adult non-Hodgkin lymphoma (NHL). In the western world it constitutes close to one third of all NHL and the estimates are even higher in the developing nations [1]. DLBCL most commonly occurs in the elderly population with slight male predominance

[1]. DLBCL that arises *de novo* is referred to as primary; whereas in cases of progression or transformation from other small B-cell lymphomas, it is referred to as secondary DLBCL and like other NHL it can initially involve either nodal or extra-nodal sites. The most common primary extranodal location is the gastrointestinal tract; however other relatively frequent sites include bone, testis, salivary gland, thyroid, liver, kidney and adrenal gland [1]. Although disseminated involvement of the female genital tract by NHL is not that uncommon, primary NHL are very rare in that location and usually involve the ovary or uterine cervix [2]. We describe a case of DLBCL of the uterine corpus that mimicked a degenerating leiomyoma on magnetic resonance imaging (MRI) and highlight both its unusual location and atypical clinical presentation.

Case Report:

A 70-years-old Caucasian woman (gravida 3, para3) presented with urinary frequency and a sense of bloating. Physical examination & review of systems were unremarkable, except as mentioned above. Past medical history was non-contributory. The patient had a 25 pack-year of smoking history. She underwent pelvic ultrasound that revealed a 3 x 3 x 2.9 cm hypoechoic

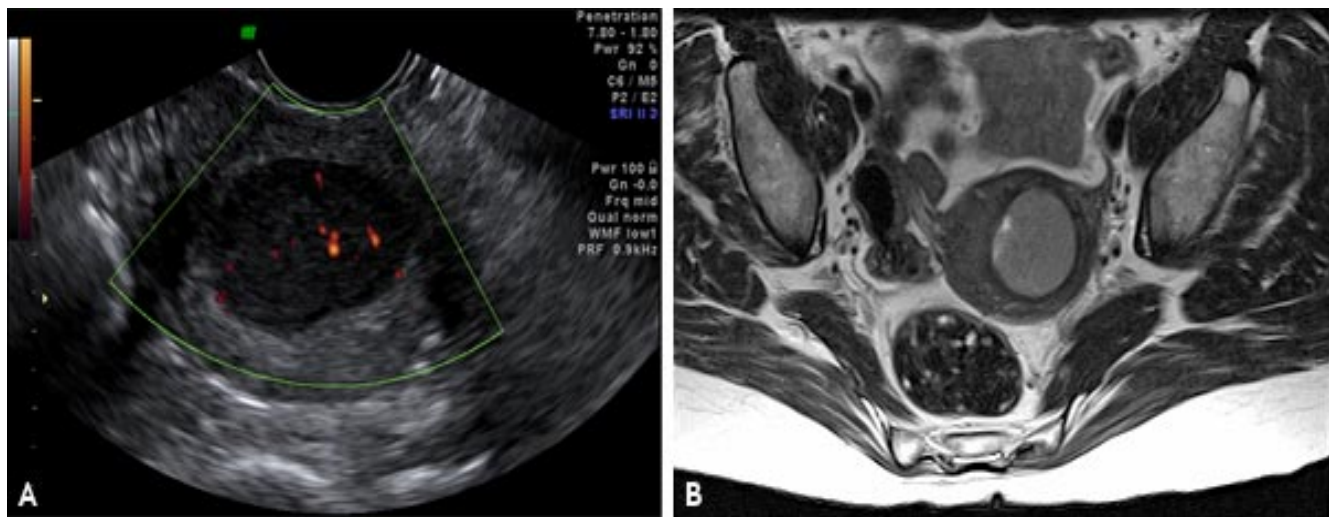


Fig1. A, Axial ultrasound image of the uterine fundus shows a well-circumscribed, homogeneously hypoechoic mass with increased through-transmission. Doppler interrogation shows internal vascularity (orange areas).

B, Axial T2-weighted MRI through the uterine fundus shows homogeneous well-circumscribed mass with myometrial and submucosal components, and resultant distortion of the endometrium.

solid lesion within the posterior wall of the uterus (Fig. 1A).

A subsequent MRI revealed a circumscribed mass in the left uterine fundus with image features most consistent with a degenerating intramural leiomyoma (Fig. 1B). The patient underwent hysteroscopy that revealed what appeared at that time a transmural fibroid extending prominently into the endometrial cavity. A significant portion of the endometrial protruding mass was removed and submitted for histologic evaluation that showed a high-grade diffuse large B-cell lymphoma. PET-CT demonstrated an fludeoxyglucose (FDG)-avid lesion confined to the uterus without evidence of other FDG-avid disease in the head, neck, chest, abdomen or pelvis. Following the histologic diagnosis, the patient was started on R-CHOP (Rituximab, Cyclophosphamide, Hydroxydaunorubicin, Oncovin and Prednisolone) chemotherapy regimen. PET imaging following three cycles of R-CHOP, showed the

previously-noted uptake within the uterus had completely resolved and the uterine fundus had decreased in size. There was no other FDG-avid disease anywhere in the body. CT scan prior to the patient's sixth and last cycle of chemotherapy showed no evidence of adenopathy or any other sign of lymphoma. Follow-up CT scan three years later showed no evidence of recurrence.

Pathologic Findings:

The tissue samples obtained by endometrial curettage had an unremarkable macroscopic appearance consisting of multiple white and pink soft tissue fragments measuring 3.5 x 3.5 x 1 cm in aggregate. Microscopic examination of the sections revealed fragments of fibrous tissue with a diffuse lymphoid infiltrate, composed predominantly of intermediate to large sized cells with round to irregular nuclear contours, prominent nucleoli, vesicular chromatin, and a moderate amount of cytoplasm. Scattered apoptotic figures were noted. No areas of tu-

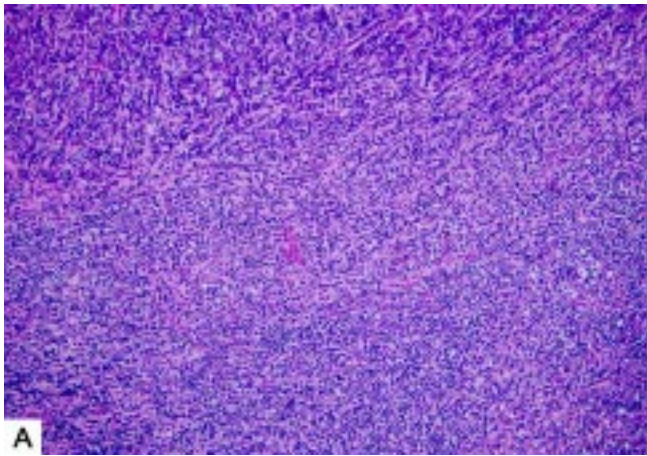
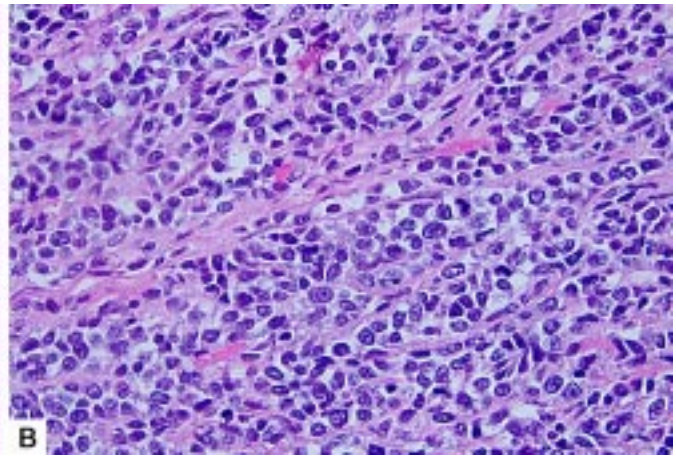


Fig. 2. A, Microscopic view of a tissue sample with diffuse lymphoid infiltration (hematoxylin-eosin, original magnification x200).



B, High-power view of the lesion demonstrating large lymphoid cells with irregular nuclei, prominent nucleoli and moderate amount of cytoplasm admixed with small lymphocytes (hematoxylin-eosin, original magnification x600).

mour necrosis were identified within the specimen. Small lymphocytes were present in the

background (Fig. 2A & B). The endometrium showed atrophic changes and otherwise was unremarkable.

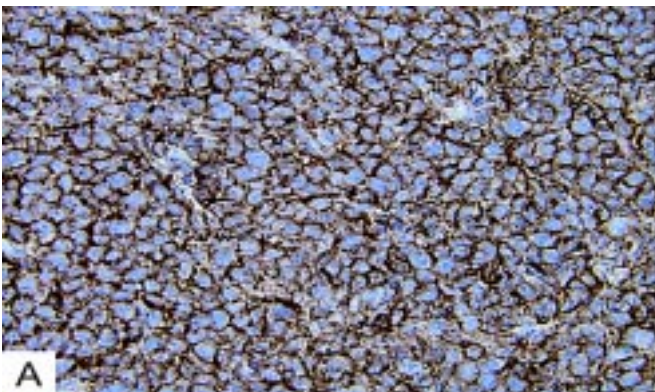


Fig. 3. A, CD20 immunoperoxidase stain (original magnification x600).

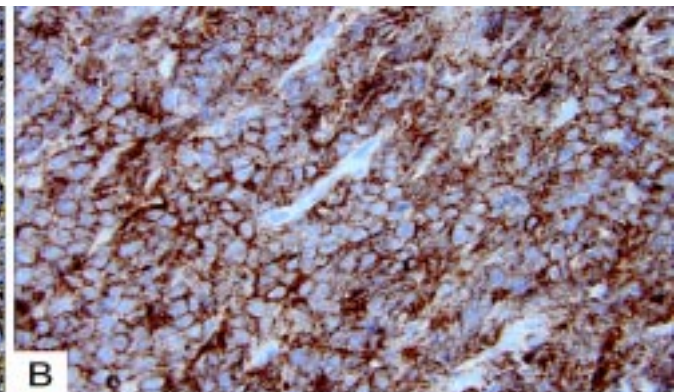


Fig. 3. B, CD10 immunoperoxidase stain (original magnification x600).

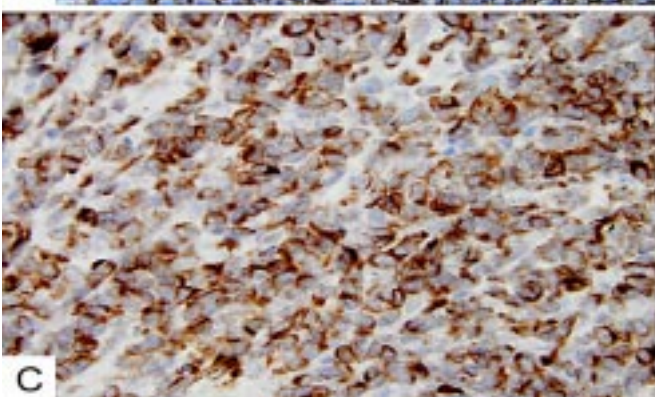


Fig. 3. C, BCL2 immunoperoxidase stain (original magnification x600).

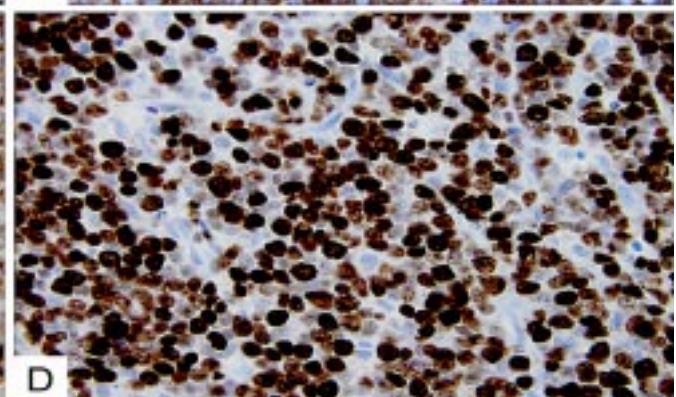


Fig. 3. D, MIB1 immunoperoxidase stain (original magnification x600)

Immunohistochemically, the tumour cells showed strong positivity for leukocyte common antigen (LCA). CD20 diffusely highlighted large B-cells (Fig. 3A). CD10, BCL2 and BCL6 were also diffusely co-expressed within the large B-cells (Fig. 3B & C).

CD3 and CD5 stained scattered T-cells. CD5 co-expression within the B-cells was not seen. DRC (dendritic reticulum cells), BCL1 and nTdT were mostly negative. MIB1 highlighted a large fraction (70-80%) of proliferating cells (Fig. 3D). The combination of morphological and immunohistochemical findings were consistent with diffuse large B-cell lymphoma. Given the absence of any other nodal or extrauterine lymphoid proliferation, the diagnosis was primary uterine lymphoma. The patient was treated with R-CHOP and followed up regularly. After 36 months of diagnosis she had no evidence of nodal or extranodal forms of lymphoma.

Discussion:

Primary NHL of the female reproductive tract is a rare entity, accounting for up to 2% of extra-nodal malignant lymphomas [3]. According to Frey et al, reviews of individual institutional databases estimate that primary lymphomas of the uterus and cervix approach a little over half a percent of all extra-nodal NHL, with uterine corpus involvement being the least common site of all [4]. An analysis of twenty-six uterine NHL cases, collected at M.D. Anderson Cancer Center over an eighteen year period, has concluded that the prevailing majority are of B-cell lineage with DLBCL being the most common histologic type [2]. In addition to DLBCL, there are less frequent reports of the uterine follicular lymphoma, marginal zone B-cell lymphoma,

small lymphocytic lymphoma and Burkitt's lymphoma [2, 4]. Primary uterine NHLs with B-cell phenotype are much more common than T-cell lymphomas and there are even fewer cases of natural killer-cell lymphomas [2, 5]. At the same time, secondary uterine involvement by any of these NHL occurs much more frequently. In fact, some reported cases of uterine lymphoma (including T-cell, small lymphocytic and Burkitt's lymphomas) lack clear evidence of being primary and likely represent lymphomas that originated in other sites [2, 4]. While primary and secondary involvement is not defined in uterine lymphomas, just as in other organ sites (e.g., primary bone lymphoma) unequivocal absence of nodal or other extranodal involvement at the time of presentation or (arbitrarily) 6 months around diagnosis may be sufficient evidence for a diagnosis of primary uterine lymphoma.

Primary uterine NHL most commonly occur in women in their mid-50's and cause a spectrum of clinical manifestations ranging from severe uterine bleeding requiring transfusions, arterial embolization and even emergent hysterectomy to being asymptomatic and diagnosed incidentally [4, 6]. Menorrhagia, metrorrhagia, irregular menses, post-coital bleeding, post-menopausal bleeding and other forms of dysfunctional uterine bleeding comprise up to two-thirds of all clinical presentations, followed by pelvic pain frequently associated with a palpable mass [2, 4]. Extrinsic compression of the bladder, as well as other urinary structures, by an enlarging mass within genital tract organs (cervix, vagina and vulva) produces in some patients urinary symptoms such as increased frequency and urgency [7]. There are also reports of pa-

tients presenting with cervical and endometrial polyps [2, 8, 9]. Asymptomatic patients have been diagnosed by routine gynecologic exams and PAP smears. In some cases, the diagnosis of uterine lymphoma could be established incidentally in total abdominal hysterectomy specimens obtained for other conditions or during post-mortem examinations [2].

We describe a case of DLBCL of the uterine corpus with an unique constellation of clinical features. To our knowledge, all previously reported cases of primary NHL localized to corpus of the uterus have manifested exclusively with abnormal uterine bleeding. Vang et al in their analysis of uterine NHL has identified only one case of a 69 years-old female who presented with increasing urinary frequency and rectal urgency, but in this patient, the lymphoma likely has originated in an extrauterine site [2]. Ours is the first case of primary lymphoma of the uterine corpus causing urinary frequency and bloating.

Prior to histologic examination, the diagnosis of leiomyoma was favoured based on radiological and clinical findings. To date, few case reports describe imaging findings of primary uterine lymphoma and there is no constellation of radiologic features that are diagnostic of uterine lymphoma. Previous descriptions reveal variable appearances, including involvement of the cervix, large infiltrative mass-like tumour, diffuse enlargement of the uterus, multilobular or septated morphology, invasion of adjacent pelvic structures (such as vagina, bladder or parametrium) and pelvic lymphadenopathy [10]. All report relatively homogeneous tumour signal on MRI, described as intermediate-to-low T1 and intermediate-to-increased

T2-weighted signal. While some case reports suggest preservation of the endometrium or junctional zone as a specific finding of uterine lymphoma, other cases have shown at least partial preservation of the endometrium or normal uterine or cervical zonal anatomy, and yet other cases have shown no normal endometrium or junctional zone [10]. In our case, both transvaginal ultrasound and MR imaging of the uterus has shown a solitary well-circumscribed, homogeneous, solid, vascularized mass with a single septation within the posterior fundus. The mass has been present in the myometrium and submucosa, causing distortion of the endometrial cavity, but with a largely preserved junctional zone. As opposed to most cases reported in the literature, there has been no evidence of invasion into adjacent pelvic structures, including the cervix, vagina, parametrium, ovaries, bladder and urethra. There has been also no lymphadenopathy demonstrated in the pelvis. On ultrasound, the mass has been hypoechoic with increased through-transmission and posterior wall enhancement, findings which mimic cysts, but given internal vascularity represents a mass or a solid lesion. This can be seen in homogeneous, cellular tumours such as lymphoma or certain metastases. Of note, this mass was not visualized on pelvic ultrasound performed little over a year prior, thus rendering benign etiology less likely in this postmenopausal patient. However, on MRI, the mass has exhibited homogeneous mildly increased T2-weighted signal and mildly decreased T1-weighted signal compared to the adjacent myometrium, as well as homogeneous mild enhancement after administration of gadolinium-containing IV contrast material, fea-

tures which may be seen in either a degenerating leiomyoma or lymphoma among other neoplasms. The combination of MRI and morphologic findings (both during hysteroscopy and gross pathology exam) of this well-circumscribed myometrial-based lesion has placed fibroid high in the differential. In fact, both gynecologists and pathologists initially have approached it as a trivial case of leiomyoma.

The histologic differential diagnosis for NHL involving the uterus includes other hematologic malignancies (i.e. Burkitt lymphoma), endometrial stromal sarcoma (ESS) and Ewing sarcoma (ES) / primitive neuroectodermal tumour (PNET). Poorly differentiated or undifferentiated carcinomas and melanoma should also be in the differential diagnosis. Prior to considering any neoplastic process, a florid benign reactive lymphoid proliferation should be excluded. In contrast to monomorphic appearing lymphomas, reactive lesions typically have non-infiltrating features and are composed of mixed populations of lymphocytes, plasma cells, neutrophils and tingible body macrophages.

Given high-grade features, relatively high proliferation by MIB1 and focal presence of apoptotic bodies seen the specimen, Burkitt lymphoma, as well as a large B-cell lymphoma, unclassifiable, with features intermediate between DLBCL and Burkitt lymphoma (Burkitt-like lymphoma) are considered in the differential diagnosis. The classic Burkitt lymphoma cytologically reveals rounded cells with moderate amounts of 'mid-night' velveteen blue cytoplasm with punched out vacuoles; nuclear features resembling a L3 (lymphoblastic) morphology, including 1-3 somewhat peripherally

placed nucleoli being frequently present. In addition, most, if not all, cases of classic Burkitt lymphoma are BCL2 negative. In our case, tumour cells are BCL2 positive with no cytoplasmic vacuoles or nuclear features that overlaps with Burkitt lymphoma. In addition, the classic "starry sky" appearance characteristic of Burkitt lymphoma seen under low power due to scattered tingible body-laden macrophages is not appreciated in the specimen. Furthermore, the patient has been treated with R-CHOP chemotherapy (standard regimen for large B-cell lymphoma) and she has remained in complete remission with no evidence of nodal or extranodal disease for more than 36 months. Burkitt or Burkitt-like lymphoma will not have responded to standard R-CHOP alone. Among other hematologic malignancies that can mimic NHL are poorly differentiated extramedullary myeloid cell tumour and Langerhans cell histiocytosis [2]. Both neoplasms lack lymphoid markers.

Distinguishing between an endometrial stromal sarcoma in particular with sex cord elements and NHL may pose an initial diagnostic challenge on H&E sections. However, absence of sarcomatoid cell spindling and prominent arborizing vasculature, as well as presence of lymphoid staining profile, provides clues to the diagnosis of lymphoma [2]. ES/PNET can have a lymphoma-like growth pattern with enlarged tumor cells, prominent nucleoli and irregular contours; however lack of lymphoid markers (except CD99) distinguishes it from NHL [2]. Due to rarity of primary NHL in the female genital tract, to date, no randomized clinical trials have been performed to outline the best approach to treatment. A variety of therapeutic

modalities and different combinations of chemotherapy, immunotherapy, surgery and radiotherapy have been reported with a range of outcomes and survival rates. One group has reported successful pregnancy occurring after chemo-radiotherapy in a 29-years-old female with DLBCL of the uterine cervix [11]. The most recent data, however, suggests that overall NHL involving rare extranodal sites including uterus have a poor prognosis with the median overall survival of slightly over 16 months [12]. The 5 year overall survival rate, as determined by a recent analysis of 28 cases of primary malignant lymphoma involving female genital tract, is 39.3% [13]. A study of surgical and non-surgical treatment modalities has concluded that chemotherapy may play a more important role than surgical intervention in treating primary genital lymphomas [14]. In regards to rituximab use, there are conflicting reports. Cvetkovic et al have reported that rituximab in combination with chemotherapy is a valuable option for patients with aggressive B-cell NHL [15]. Yun et al, on the other hand have indicated that a combination of rituximab and chemotherapy (CHOP) failed to provide an additive survival benefit over the same chemotherapy alone [12].

In summary, we have reported a case of primary DLBCL involving exclusively uterine corpus and presenting with urinary symptoms and sense of bloating. Imaging findings have included a relatively wide differential diagnosis including lymphoma and degenerating leiomyoma depending on the study. Although lymphoma of the female genital tract has an exceedingly low incidence, it should be kept in mind in patients presenting with persistent uri-

nary symptoms and sense of bloating. Whenever features of leiomyoma, especially degenerating, are seen on MR imaging, uterine lymphoma should also be considered in the differential diagnosis.

References:

1. Stein H, Warnke RA, Chan WC, et al. Diffuse large B-cell lymphoma, not otherwise specified. In: Swerdlow SH, Campo E, Harris NL, et al, eds. *WHO Classification of Tumours of Haematopoietic and Lymphoid Tissues*, 4th ed. Lyon, France: IARC; 2008:233-234.
2. Vang R, Medeiros LJ, Ha CS, Deavers M. Non-Hodgkin's lymphomas involving the uterus: a clinicopathologic analysis of 26 cases. *Mod Pathol* 2000; 13(1):19-28.
3. Shen CJ, Tsai EM, Tsai KB, Wu CH, Hsu SC. Primary T-cell lymphoma of the uterine corpus. *Kaohsiung J Med Sci* 2007; 23(3):138-41.
4. Frey NV, Svoboda J, Andreadis C, Tsai DE, Schuster SJ, Elstrom R, Rubin SC, Nasta SD. Primary lymphomas of the cervix and uterus: the University of Pennsylvania's experience and a review of the literature. *Leuk Lymphoma* 2006; 47(9):1894-901.
5. Mhawech P, Medeiros LJ, Bueso-Ramos C, Coffey DM, Gei AF, Shahab I. Natural killer-cell lymphoma involving the gynecologic tract. *Arch Pathol Lab Med* 2000; 124(10):1510-3.
6. Bode MK, Tikkakoski T, Johansson J, Johansson K, Kariniemi J, Apaja-Sarkkinen M, Tuominen H. Lymphoma of the cervix. Imaging and transcatheter arterial embolization. *Acta Radiol* 2002; 43(4):431-2.

7. Amichetti M, Chiappe E, Mussari S, Busana L, Caffo O, Botto F, Galligioni E, Tomio L. Primary non-Hodgkin's lymphoma of the female genital tract. *Oncol Rep* 1999; 6(3):651-4.
8. Rossi G, Bonacorsi G, Longo L, Artusi T, Rivasi F. Primary high-grade mucosa-associated lymphoid tissue-type lymphoma of the cervix presenting as a common endocervical polyp. *Arch Pathol Lab Med* 2001; 125(4):537-40.
9. Rittenbach J, Cao JD, Weiss LM, Rowsell EH, Chick W, Wang J. Primary diffuse large B-cell lymphoma of the uterus presenting solely as an endometrial polyp. *Int J Gynecol Pathol* 2005; 24(4):347-51.
10. Goto N, Oishi-Tanaka Y, Tsunoda H, Yoshikawa H, Minami M. Magnetic resonance findings of primary uterine malignant lymphoma. *Magn Reson Med Sci* 2007; 6(1):7-13
11. Ferreri AJ, Verona C, Bolognesi A, Taccagni G, Ponzoni M, Ferrari S. Successful pregnancy after chemo-immuno-radiation therapy for aggressive lymphoma of the uterus. *Br J Haematol* 2008; 142(1):141-3.
12. Yun J, Kim SJ, Kim JA, Kong JH, Lee SH, Kim K, Ko YH, Kim WS. Clinical features and treatment outcomes of non-Hodgkin's lymphomas involving rare extranodal sites: a single-center experience. *Acta Haematol* 2010; 123(1):48-54.
13. Su CF, Tsai HJ, Kuo C, Chen GD, Lin LY, Huang CC, Luo KH. Primary non-Hodgkin's lymphoma of the uterus, cervix and parametrium treated by combined immunochemotherapy. *J Obstet Gynaecol Res* 2008; 34(4 Pt 2):749-53.
14. Signorelli M, Maneo A, Cammarota S, Isimbaldi G, Garcia PR, Perego P, Pogliani E, Mangioni C. Conservative management in primary genital lymphomas: the role of chemotherapy. *Gynecol Oncol* 2007; 104(2):416-21.
15. Cvetkoviæ RS, Perry CM. Spotlight on rituximab in non-Hodgkin lymphoma and chronic lymphocytic leukemia. *Bio Drugs* 2006; 20(4):253-7.

***Author for Correspondence:** Rajan Dewar, MD, Ph. D., Beth Israel Deaconess Medical Center / Harvard Medical School, Department of Pathology, 330 Brookline Avenue, Yamins 309, Boston, MA 02215, USA, Tel: 617-667-3648, Email: rdewar@bidmc.harvard.edu