

CASE REPORT

Primary Bilateral Non Hodgkin's Ovarian Lymphoma – A Case Report

Sunita S. Dantkale^{1*}, Gopal A. Pandit¹, Supriya S. Joshi¹, Smita S. Pudale¹

¹Pathology Department, Dr. V. M. Govt. Medical College, Civil Chowk,

Solapur-413003, (Maharashtra), India

Abstract:

Background: Involvement of the ovary by malignant lymphoma is a well known late manifestation of disseminated nodal disease. Primary ovarian lymphoma is rare. *Case History:* We report an autopsy case of primary ovarian non Hodgkin's lymphoma with bilateral involvement. A 30 years old woman was admitted with signs and symptoms suggestive of an ovarian cancer. Computed tomography revealed two abdominal masses measuring 10cm in diameter, without enlarged lymph nodes. Patient died on second day of treatment, so her autopsy was performed. Diagnosis of malignant lymphoma was made on histopathology. Tumour was classified as a diffuse large B cell lymphoma with the help of immunohistochemistry. Absence of disease in blood and bone marrow, no lymphadenopathy favours the diagnosis of primary lymphoma.

Key words: Primary Lymphoma, Ovary, Autopsy

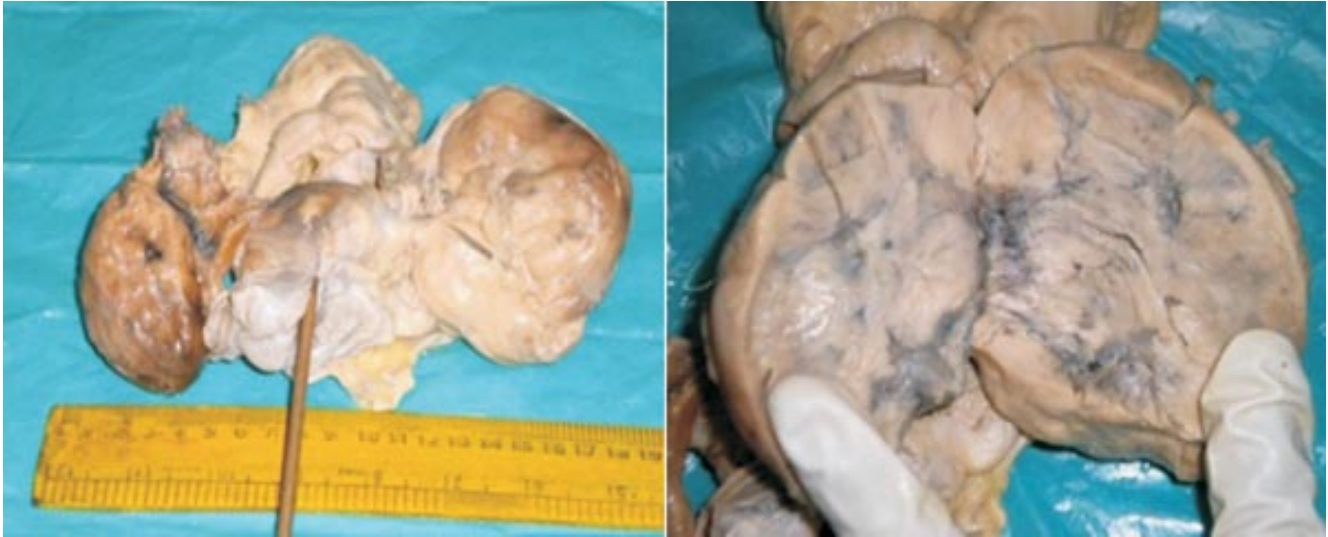Introduction:

Secondary ovarian involvement by malignant lymphoma is a well recognized entity and has been reported in 20-30% of cases in some autopsy series [1]. The occurrence of bilateral primary ovarian lymphoma is quite rare and

accounts for 0.5% of non Hodgkin's lymphomas and 1.5% of all ovarian neoplasms with diffuse large B cell lymphoma being the commonest type [2]. We present here an autopsy case of primary bilateral ovarian non Hodgkin's lymphoma.

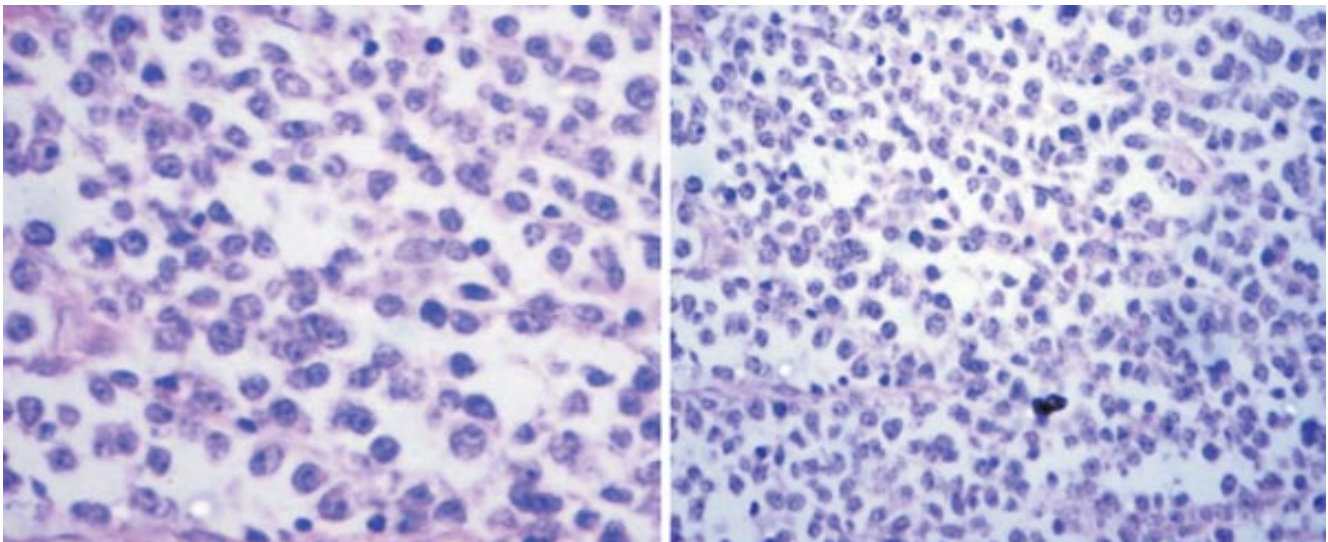
Case Report:

A 30 years old female was admitted in our hospital with pain and distension of abdomen, pedal oedema, and breathlessness since seven days. Physical examination revealed an abdominopelvic mass of size 10x6 cm. CT abdomen showed two ovarian masses with no evidence of abdominal lymphadenopathy. Her haematological profile was within normal limit. Within two days of admission the patient succumbed to death and her autopsy was performed. On autopsy abdominal cavity revealed 500cc dark yellow fluid and bilaterally enlarged ovaries. A segment of large intestine was adherent to left ovary. Both kidneys showed small gray white nodules on the cortical surface. All the organs were subjected to histopathological examination and differential diagnosis of dysgerminoma and non Hodgkin's ovarian lymphoma was made. Immunohistochemistry confirmed the diagnosis of diffuse large B cell lymphoma.

Histopathology:

Gross- Uterus with bilateral adnexa along with an adherent segment of large intestine together measured 20x10x5cm. Left ovary measured 9x5x3cm and right ovary measured 6x4x3cm. External surfaces of both ovaries were nodular, gray white and cut surface showed diffuse, homogenous, fleshy, gray white to tan coloured mass replacing the ovarian tissue with few areas

of haemorrhages. Both fallopian tubes and adherent segment of intestine showed diffuse thickening of the wall. Uterus and cervix were grossly unremarkable. Mesentery showed diffuse thickening with multiple gray white nodules. Cortical and cut surface of both kidneys showed 2-3 tiny gray white nodules.

Microscopy:

Sections from bilateral ovarian masses showed tumour with diffuse solid pattern composed of monotonous large round cells with round to oval nucleus having coarse chromatin, 1-2 prominent nucleoli and scanty cytoplasm. Interspersed between these cells tingible body macrophages are seen. So diagnosis of non Hodgkin's lymphoma was made supported by Immunohistochemistry which showed positivity of tumour cells for B lineage markers (CD20 and CD79a) and negativity for T lineage markers (CD3 and CD138). Also it showed only 30% Mib1 activity which is lower as compared to high proliferative activity in case of Burkitt's lymphoma [10].

Sections from bilateral fallopian tubes, mesentery, parametrium, large intestine and both kidneys showed infiltration by tumour cells with similar morphology as described above. Sections from uterus and cervix were free from tumour invasion.

Discussion:

Malignant lymphoid tumours of female genital tract are unusual, although the ovaries are the most common sites to be affected (25%) [3]. The ovarian involvement in malignant lymphoma may be primary or secondary [4]. The distinction is important because primary extra nodal lymphoma runs a less aggressive course with 5 year survival rate of 80% as compared to secondary malignant lymphoma, which has a 5 year survival rate of only 33% [5].

As suggested by Fox *et al*, diagnostic criteria for primary ovarian lymphoma are a) a disease confined to ovary, b) absence of disease in blood and bone marrow; c) the extra ovarian

deposits if any should appear at least after few months [1]. But diagnosis of primary lymphoma may still be considered if the spread has occurred to the adjacent lymph nodes or to the immediately adjacent structures [1, 8]. In our case there was no obvious lymphadenopathy and blood, bone marrow, spleen or hepatic involvement. Adjacent structures like fallopian tubes, parametrium and broad ligament were involved. All these findings favour the diagnosis of primary ovarian lymphoma.

Lymphomas of the ovary may occur at any age, but mostly women in their 40s are affected [3, 5, 7, 8]. Whether primary or secondary, ovarian lymphomas may have varied presentation, most of them being discovered incidentally during the work up for pelvic or abdominal complaints [3, 7, 8]. Patients presenting with rapid onset abdominal pain and distension had worse prognosis [6]. Our patient also presented with rapid onset of abdominal pain and distension which proved fatal.

Malignant lymphoma of the ovary may be confused with other primary ovarian tumours like dysgerminoma, [1,9] granulocytic sarcoma, [3,4,9] granulosa cell tumor, [3,4] undifferentiated carcinoma and metastatic breast carcinoma, [3,4,6] of which dysgerminoma is the commonest which mimics lymphoma both microscopically and macroscopically [1,7] Only 10% of dysgerminomas are bilateral in contrast to 50% of the lymphomas [1, 4, 9]. Microscopically the cells of dysgerminoma are uniform with PAS+ve, diastase sensitive, clear cytoplasm whereas in lymphoma cytoplasm is scanty and PAS negative [3].

Granulocytic sarcoma on routine stains is often

composed of cells with more finely dispersed chromatin and abundant deeply eosinophilic cytoplasm compared to lymphoma cells which have nuclei of same size with coarse chromatin and scanty cytoplasm. The findings of granulated myelocytes are diagnostic of granulocytic sarcoma [3, 9].

The single file arrangement of lymphoma cells may simulate metastatic carcinoma particularly one of breast origin [6, 9] However in such cases history of primary mammary carcinoma is present. Morphologically cells in breast carcinoma have irregular margins, they retain their intercellular attachments, form cohesive sheets and at times produce small amount of intracytoplasmic mucin [4].

Granulosa cell tumours are distinguished from lymphoma by grooved nuclei, formation of Call- Exner bodies and tendency to merge with thecomatous areas [4].

At laparotomy extra ovarian involvement is found in 2/3rd of patients with lymphoma as seen in our case [9]. Diffuse infiltration of the adjacent fallopian tubes and broad ligament found in our case is more commonly seen in lymphomas than in other primary and metastatic tumours of the ovaries [3, 9].

Immunohistochemistry in our case showed positivity of tumour cells for B lineage markers (CD20 and CD79a) and negativity for T lineage markers (CD3 and CD138). Also it showed only 30% MIB1 activity which is lower as compared to high proliferative activity in case of Burkitt's lymphoma [10]. On the basis of microscopic findings supported by immunohistochemistry, [1 2 6] diagnosis of primary non Hodgkin's lymphoma of the ovary was made.

Conclusion:

Primary non Hodgkin's ovarian lymphoma is rare. It needs to be differentiated from other ovarian malignancies, as its management differs from other primary and metastatic ovarian tumours

References:

1. Deepti A, Sangeeta S, Rani B, Shikha S. Primary Bilateral Ovarian Non Hodgkin's Lymphoma. *Journal of Clinical Diagnostic Research* (serial online) 2010 October; 4: 3212-3214.
2. Elharroudi T, Ismaili N, Errihani H, Jalil A. Primary lymphoma of the ovary. *J. Can Res Ther* 2008; 4:195-196.
3. Osborne BM, Robboy SJ. Lymphoma or Leukaemia Presenting as ovarian Tumours: An analysis of 42 cases. *Cancer* 1983; 52:1933-1943.
4. Chorlton I, Norris HJ and King FM. Malignant Reticuloendothelial Disease Involving the Ovary as A Primary Manifestation - A series of 19 lymphomas & 1 granulocytic sarcoma. *Cancer*; 34:397-407.
5. Julian A, Crasta and Elizabeth Vallikad. Ovarian Lymphoma. *Indian J Med Paediatr Oncol* 2009 Jan- Mar; 30(1):28-30.
6. Fox H, Langley FA, Govan AD, Hill AS, Bennett MH. Malignant Lymphoma Presenting as an Ovarian Tumour: A Clinicopathological Analysis of 34 cases. *Br J Obstet Gynaecol* 1988; 95:386-90.
7. Vang R, Madeiros J, Warnke RA, Higgins JP, Deavers MT. Ovarian Non Hodgkin's Lymphoma: Clinicopathologic Study of

-
- Eight Primary Cases. *Mod Pathol* 2001; 14:1093-1099.
8. Monterroso V, Jaffe ES, Merino MJ, Medeiros LJ. Malignant Lymphomas Involving the Ovary. *Am J Surg Pathol* 1993; 17:154-1703.
9. Ray S, Mallick MG, Pal PB, Chaudhary MK, Bandopadhyay A, Guha D. Extranodal Non Hodgkin's Lymphoma Presenting as an Ovarian Mass. *Indian J Pathol Microbiol* 2008; 51:528-530.
10. Gokalp Oner, Tuncay Ozgun, Bulent Ozcelik, Serdar Serin, Figen Ozturk. Primary Ovarian Burkitt's lymphoma Mimicking an Advanced Ovarian Tumour: A case report. *Erciyes Tip Dergisi online* 2010; 32:283-286.
-

***Author for Correspondence:** Dr. Sunita S. Dantkale, Department of Pathology,
Dr. V.M. Govt. Medical College, Civil Chowk, Solapur-413003 (MS)
Cell – 9890222727, Email– drjoshisupriya@gmail.com , sunitadantkale9@gmail.com