
ORIGINAL ARTICLE**The relationship between metatarsophalangeal, metatarsocuneiform and naviculocuneiform joint angles: An anatomical investigation in an Anatolian population***Berin Tuğtağ Demir^{1*}, Murat Üzel²**¹Ankara Medipol University, Faculty of Medicine, Department of Anatomy, Ankara, Turkey, ²Kocaeli University, Faculty of Medicine, Department of Orthopaedics and Traumatology, Kocaeli, Turkey*

Abstract

Background: Function of the first Naviculocuneiform (NC) joint has long been the subject of discussion, debate and controversy. *Aim and Objectives:* To investigate the effects of the tendons of peroneus longus and tibialis anterior muscles as well as the association of those interactions with the metatarsophalangeal, metatarsocuneiform and naviculocuneiform joints. *Material and Methods:* This research was performed on thirty-two lower limbs of adult cadavers (Anatolian population, age range 40-65 years). Study population for these lower extremities comprised 12 (37.5%) females and 20 (62.5%) males. Twenty one of the limbs were from the right extremity, 11 of them were from the left extremity. The specimens with fracture, previous surgery or arthritis were excluded. While the foot was located in anatomical position, the angles for metatarsophalangeal, metatarsocuneiform and naviculocuneiform joints in the metatarsal and sagittal planes were photographed after inserting 8-10 cm long needles. These angles were calculated by using CorelDRAW 5.00. *Results:* In the horizontal plane, it was found that the angle for metatarsophalangeal joint was between 4.5°-10° in females and 3.8°-9.9° in males and the angle for metatarsocuneiform joint was between 5.1°-12.6° in females and 2.7°-12.3° in males. Similarly, the angle for naviculocuneiform joint was measured between 2.1°-9.4° in females and 3°-11.4° in males. Intermetatarsal angle varied between 6°-11.2° in males and 5.5°-11° in females. *Conclusion:* Normal values of the angles of those joints should be kept in mind since evaluation of patient's foot deformity will be based on these results. Hence, the severity of patient's foot deformity will be assessed according to the results of those analyses in deciding the conservative or surgical treatment.

Keywords: Metatarsophalangeal Joints, Naviculocuneiform Joints, Cadaver, Anatolian Population, Lower Extremity

Introduction

First Metatarsophalangeal (MTP) and first Metatarsocuneiform (MC) joints are the key structures in a variety of disorders, including osteoarthritis associated with hallux limitus and rigidus, hallux varus, severe hallux abductovalgus, recurrent hallux valgus, and rheumatoid foot deformity [1-2]. But function of the first Naviculocuneiform (NC) joint has long been the subject of discussion, debate and controversy. The normal range of dorsiflexion is 50°-60°, and

plantarflexion is 35°-50° motion at the first MTP joint [3]. While walking, required average is 65° hallucal dorsiflexion [3-4]. Other MTP joints have movement of 40° dorsiflexion, 40° plantarflexion. Angles of MTP joint ranging from 15° to 40° extension in relation to the metatarsal and a valgus angle between 15° and 30° have been recommended [5].

MC hypermobility is generally deformity of accompanying high degree hallux valgus [6-8].

MC is considered as normal if it is flat or has a medial angulation less than 10° . Joint is not stable if it has more obliqueness. There is no information about joint-angle relation for NC joint in literature. Clinically, any variation in measuring those angles between surgeons or by the same surgeon on different occasions could affect the selection of the appropriate surgical procedure. In addition to great deal of research, many methods have been described to measure MTP and MC angles. Using different methods cannot give the same results and lead to more clutter. Function of the first MC and first NC joint has long been the subject of discussion, debate, and controversy. Nevertheless, many other reports have claimed an association between increased first MC and first NC joint or first ray mobility and hallux disorders [9-10]. MTP, MC and NC joints that are the center of foot biomechanics are important not only for degenerative arthritis such as hallux valgus, hallux varus and hallux rigidus but also protection of the medial arch of foot [11-13]. For this reason, the aim of our study was to reveal connections and relationships of angles of MTP, MC and NC joints by determining the value in the horizontal and sagittal plane with a clinical perspective.

Material and Methods

Ethics

This study was conducted at Kahramanmaraş Sutcuimam University Faculty of Medicine (Kahramanmaraş, Turkey) from 17th March 2014 to 20th November 2014. It was approved by the local research committee at the medical faculty of Kahramanmaraş Sütçü Imam University (2013/12-5).

Cadavers

This research was performed on thirty-two lower limbs of adult cadavers (Anatolian population, age range 40-65 years). Study population for these lower extremities comprised 12 (37.5%) females and 20 (62.5%) males. Twenty one of the limbs were from the right extremity and 11 were from the left extremity. In order to determine the number of samples, power analysis was performed using the G*Power (v3.1.9.7) program. The power of the study is expressed as $1 - \beta$ (β = probability of type II error). In the calculation made, the effect size (d) was found to be 0.540 to obtain 90% power at $\alpha=0.05$ level. Accordingly, it was calculated that there should be at least 31 lower extremity samples in the study. The specimens with fracture, previous surgery or arthritis were excluded.

Preparation

The lower limbs were amputated by the Department of Orthopaedics and Traumatology with various medical indications. They had been donated to the university Orthopaedics and Traumatology department to be used as cadavers and were property of the department. They were carefully inspected for foot deformities and the ones with evidence of surgical intervention in the dissected area were excluded. All dissections of the leg and foot area were performed in accordance with a preestablished protocol [14-15]. Amputated lower limbs were stored in the freezer at -15°C until the dissection. After taking out of the freezer and 12 hours waiting period at room temperature, dissection procedure was carefully performed.

Dissection

The procedure began with the removal of the skin and superficial fascia of the leg up to the crural-fascia. A longitudinal skin incision was made that began at the anterior part of the distal one-fourth of the leg. Each specimen was transected at the tibial and fibular shafts, 40 cm proximal to the heel, and the skin was removed from the specimen while preserving the intrinsic muscles, tendons and ligaments of the foot. The dissection of the foot was performed while maintaining the position of the MTP, MC and NC joints and showing the maximal core. The first metatarsal joint structures and faces were preserved and completely exposed. All soft and connective tissues were removed. None showed signs of previous major surgery around the

foot or ankle or any relevant deformities, and there was no obvious degeneration in any specimen. All measurements were made to the nearest millimeter, accomplished with an analogue calliper. Photographs were taken during the entire procedure.

Measures

Firstly, tibia, foot length and foot width were measured. Horizontal and sagittal plane, MTP, MC and cuneonavicular joint were made distinctive. Then while feet being in anatomical position, angles of MTP, MC and NC in the horizontal and sagittal plane were photographed by using 8-10 cm needles inserted into these joints (Fig. 1).

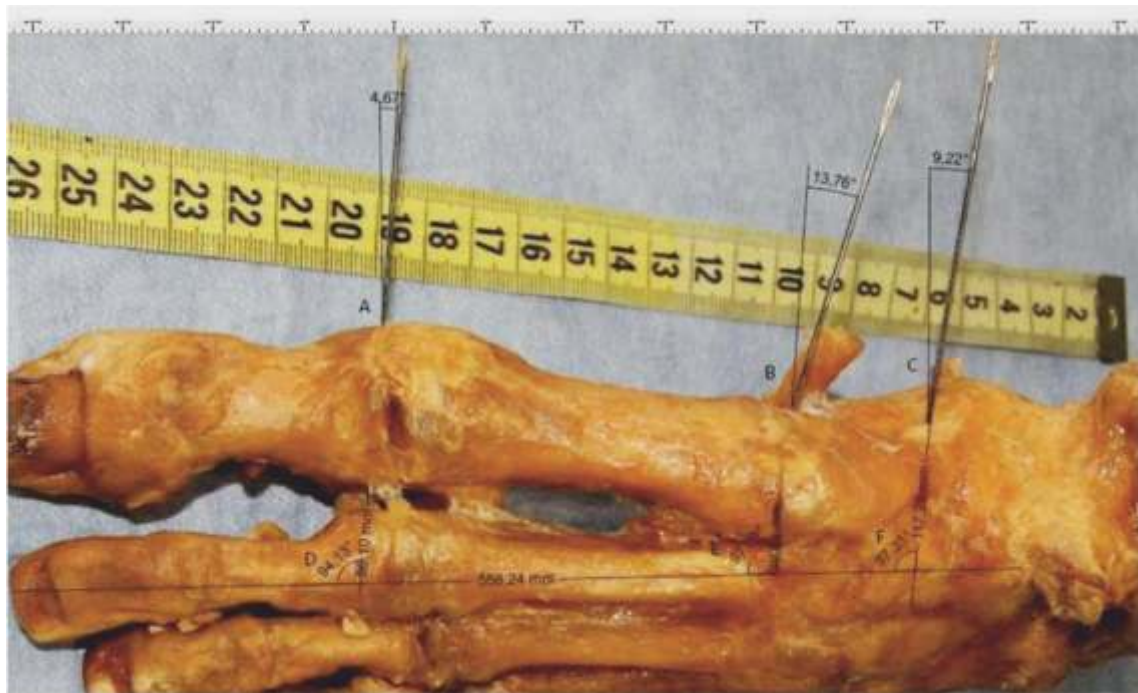


Figure 1: Measurement of MTP (A), MC (B), NC (C) joints in the horizontal plane and measurement of foot midline with this three joints. MTP B2 (D), MC B2 (E), NC B2 (F)

A. In horizontal plane: Medially each needle determined two angles.

A-1. The angle with the metatarsal shaft axes

A-2. The angle between the longitudinal axis of the metatarsals and foot midline passing through heel centerline. (Foot midline was determined based on the midline of the second finger)

B. In sagittal plane: Laterally each needle determined two angles.

B.1 The angle with the metatarsal shaft axes

B.2 The angle with the axis of the sole of the foot
Then while feet being in anatomical position, Anteroposterior (AP) and lateral planes' photos were taken in terms of equal distance. These angles were calculated by using CorelDRAW 5.00. In each of the two planes, six angles were measured.

Primary assessment criteria

The measurements were made separately by 3 independent researchers while the foot was in the supine position, and the consistency of the results was tested. During the measurements, attention was paid to ensure that the needle passes right through the middle of the joint and is in the required plane. MTP, MC, and NC joint angles were measured in CorelDRAW program by carefully photographing both horizontal and sagittal planes (Fig 1).

Secondary assessment criteria

To define angle for each joint, the 3 observers measured the position of each needle (MTP, MC and NC joints) relative to the vertical line in the coronal plane for each specimen under neutral condition. We also assessed the inter-observer reliability of these measurements. This study examined the intra-rater reliability of morphological characteristics, with retesting performed at an interval of 3-7 days.

Statistical analyses

All statistical analyses were performed using SPSS for Windows. The normality of the continuous data were tested using the Shapiro-Wilk test. As the data were not normally distributed, non-parametric tests were used. These measurements were used to calculate percentages. Morphological measurements between two groups were compared using the Mann-Whitney test. Spearman's non-parametric test was applied to correlate the between joints. The level of significance was taken to be 0.05.

Results

The bones were measured as follows; tibia length 34.3 cm, leg length 21 cm, leg width 8 cm for females and tibia length 37.5, foot length 24.5 cm, foot width 8.7 cm for males.

In the horizontal plane, it was found that the angle for MTP joint was between 4.5°-10° in females and 3.8°-9.9° in males and the angle for MC joint was between 5.1°-12.6° in females and 2.7°-12.3° in males. No statistical significance was found in the comparison of the right and left sides of the angles ($p > 0.05$) (Table 1). Similarly, the angle for NC joint was measured between 2.1°-9.4° in females and 3°-11.4° in males. Intermetatarsal angle varied between 6° -11.2° in males and 5.5° - 11° in females. The relationship between joint angles is given in Table 2.

MTP, the MC and MC joint angles showed compatibility with the angle of metatarsal shaft axes and the angle between the longitudinal axis of the metatarsals and foot midline passing through heel centerline. It was also found to be parallel between angles (Fig.2). The angle of MTP in sagittal plane with the sole of the foot was correlated with foot length and foot width.

Statistical analysis was done using SPSS for Windows. The length of tibia and the angle of NC joint in sagittal plane were statistically ($p \leq 0.01$) positively correlated, while there was a negative correlation with MC joint and the length of tibia. In other words, the angle of MC joint decreases whereas the angle of NC joint increases as the length of tibia increases.

One of our most important results was that MTP in horizontal plane and MC in the sagittal plane were associated with each other ($p \leq 0.01$) and they had a positive correlation.

Table 1: In horizontal and sagittal plane, the joint angles in the first metatarsal bone (°)

Sex		Horizontal Plane (°)						Sagittal Plane (°)					
		MTPA1	MC A1	NCA1	MTPA2	MC A2	NC A2	MTP B1	MC B1	NC B1	MTP B2	MC B2	NC B2
Female	Right	7.0	6.9	6.4	92.6	91.5	94.9	8.6	20.4	7.9	78.5	66.0	74.1
	Left	6.6	6.5	5.9	86.9	85.3	88.1	7.5	20.6	7.5	75.8	61.1	67.4
Mean		6.8	6.7	6.1	89.7	88.4	91.5	8.0	20.5	17.7	77.1	63.5	70.7
z/p		0.45/ 1.24	-0.29/ 0.34	2.89/ 1.41	-0.79/ 0.42	4.50/ 1.24	3.82/ 0.78	0.61/ 0.56	-0.14/ 0.22	1.78/ 0.45	1.84/ 0.60	1.89/ 1.24	-1.01/ 0.26
Male	Right	7.5	6.8	5.8	93.4	92.0	94.2	9.7	23.5	20.1	71.1	64.3	68.3
	Left	7.0	7.6	7.288	92.7	87.6	89.9	8.0	18.6	14.4	69.9	54.9	67.8
Mean		7.2	7.2	6.5	93	89.8	92	8.8	21	17.2	70.3	59.6	68
z/p		-1.83/ 0.06	-1.88/ 0.099	-2.34/ 0.26	-0.75/ 0.54	-0.25/ 0.80	0.60/ 0.40	-2.01/ 0.26	-0.045/ 0.26	-0.67/ 0.40	-0.25/ 0.80	-0.95/ 0.34	0.90/ 0.84

Test: Mann Whitney U, MTP: Metatarsophalangeal joints, MC: Metatarsocuneiform joint, NC: Naviculocuneiform joints;
 In the horizontal plane: A1: The angle with the metatarsal shaft axes, A2: The angle between the longitudinal axis of the metatarsals and foot midline passing through heel centerline. (Foot midline was determined based on the midline line of the second finger);

In sagittal Plane: B1: The angle with the metatarsal shaft axes, B2: The angle with the axis of the sole of the foot

Table 2: Determining the relationships of MTP, MC and NC joints angles in the horizontal and sagittal planes with the Spearmon's Rho correlation test

		Horizontal						Sagittal					
		MTPA1	MC A1	NC A1	MTPA2	MC A2	NCA2	MTPB1	MC B1	NC B1	MTPB2	MC B2	NCB2
Horizontal	MTPA1			0.480 (**)				0.575 (**)		0.409 (*)		0.393 (*)	
	MCA1											-0.404 (*)	
	NC A1	0.480 (**)				0.494 (**)		0.491 (**)					
	MTPA2					0.461 (**)			0.515 (**)	0.473 (**)			-0.504 (**)
	MCA2				0.461 (**)								
	NCA2			0.494 (**)		0.455 (**)							0.427 (*)
Sagittal	MTPB1	0.575 (**)		0.491 (**)						0.524 (**)	-0.532 (**)		
	MC B1				0.515 (**)								
	NCB1	0.409 (*)			0.473 (**)			0.524 (**)					-0.602 (**)
	MTPB2							-0.532 (**)					
	MC B2												
	NC B2				-0.504 (**)						-0.602 (**)		

MTP: Metatarsophalangeal joints, MC: Metatarsocuneiform joint, NC: Naviculocuneiform joints; In the horizontal plane: A1: The angle with the metatarsal shaft axes, A2: The angle between the longitudinal axis of the metatarsals and foot midline passing through heel centerline0. (Foot midline was determined based on the midline line of the second finger); In sagittal Plane: B1: The angle with the metatarsal shaft axes, B2: The angle with the axis of the sole of the foot*P<0,05; **<0,001

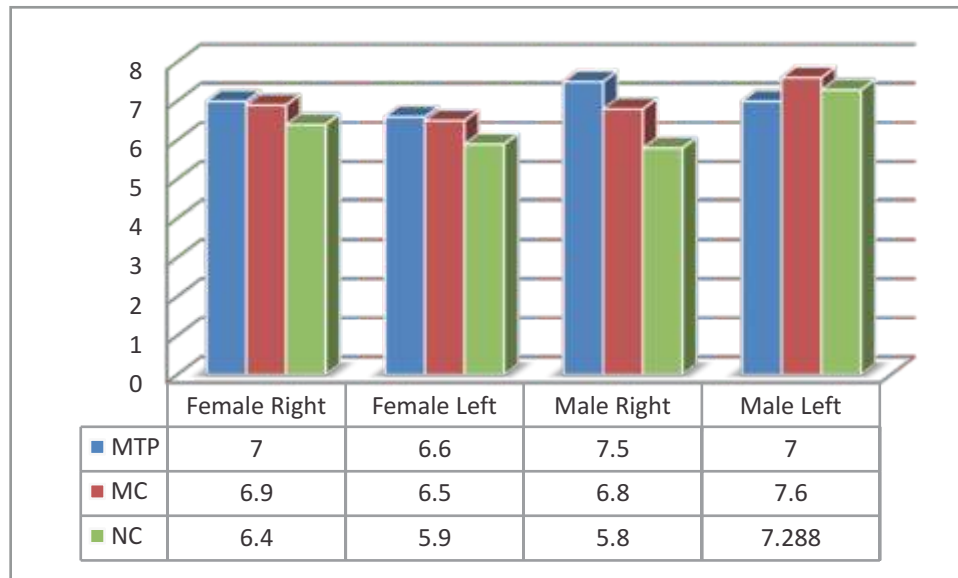


Figure 1: In the horizontal plane, MTP, MC and NC angles (°)

MTP: Metatarsophalangeal joints, MC: Metatarsocuneiform joint, NC: Naviculocuneiform joints

Discussion

There has not been any study in literature demonstrating the relation between NC, MTP and MC and their effect on deformities. There has been no study about angles between these three joints in sagittal and horizontal plane and correlation between them either. NC, MTP and MC are important not only for hallux valgus, hallux varus and hallux rigidus which are degenerative arthritis but also for protection of the medial arch of the foot [11, 16-17]. That is why angles are examined in sagittal plane in addition to horizontal plane. NC joint is affected in both sagittal and horizontal plane by the angle with MTP joint in horizontal plane, whereas MC joint is in balance by adjusting angle with foot in just sagittal plane. The angle of MC in sagittal plane decreases as the angle of MC in horizontal plane increases. That is how foot can remain in healthy anatomic structure within normal limits.

The most striking result of our study was the determination of real-time measurements of MTP, MC and NC joint angles. According to our results, it was determined that the mean angulation of the metatarsal shaft axis was 7° in the MTP, 6.9° in the MC, and 6.3° in the NC in the horizontal plane. It is extremely difficult to determine the MTP, MC and NC angles during the operation in foot surgery. Although CT is accepted as the gold standard theoretically, it is a complicated method that requires a lot of time, cost and experience to determine the proximal and distal joint angles by performing CT during the surgical procedure. In addition, it is extremely difficult to determine these joint angles with their actual values in the AP and sagittal planes during the operation. Although CT is taken before and after the operation, knowing the relevant joint angles during the surgical procedure will undoubtedly affect the patient's health

positively. In fact, in foot operations, some surgeons try to determine the joint angle by passing a thin needle through the tarsal joints. However, there is no literature information about the extent to which this procedure reflects the true angle value of the joint. Therefore, in this study, we aimed to determine the MTP, MC, NC and intermetatarsal joint angles in cold fresh amputees in a way that would be most appropriate to their actual values.

Value of the angle of MTP joint which is the angle of hallux valgus is normally between 8° - 10° . Some authors express that it could be less than 15° [5, 16, 18]. It is considered as hallux valgus in literature when the angle is over 20° . It was found that the angle of MTP was 27° with ground in lateral plane. This angle is considered as declination angle of os metatarsale I and it is regarded as base to take decision about osteotomy procedures [19-21]. Beeson [16], gives 25° for declination angle, whereas Lundeen *et al.* [20], gives 30° .

In our study, it was determined that the mean angle of MTP A2 in the sagittal plane was 73.7, that of MC A2 was 61.5, and that of NC A2 was 69.3 on average. In their studies investigating the relationship of the first metatarsal joint opening with the capsule; Xu *et al.* (2017) and Jones *et al.* [2005] reported the MTP A2 angle as 63.2 and 62.2; respectively [22-23]. No findings were found regarding the sagittal A2 measurements of the MC and NC in the scans. However, relatively more studies have been carried out on MTP because the movement of the MTP joint is very important for the functional biomechanics of the forefoot. When the dorsiflexion of the MTP joint is below the range of 30 to 40° , the joint is strained during the pushing motion [24-25]. Whatever

surgical method is chosen in foot surgeries such as hallux valgus, it should be aimed to permanently correct the deformity and relieve pain without limiting the MTP angle in order to preserve the functional biomechanics of the forefoot.

MTP, MC and NC are important not only in degenerative arthritis such as hallux valgus, hallux varus and hallux rigidus, but also in the preservation of the medial arch of the foot [11]. Therefore, in our study, we evaluated not only the values of the angles in the horizontal plane, but also the angles in the sagittal plane. These results show us that the NC is affected in both the sagittal and horizontal planes of the joint from the angle of the MTP in the horizontal plane, but it provides balance by increasing the angle of the MC joint with the foot only in the sagittal plane. In addition, as the angle of the MC in the horizontal plane increased, its angle in the sagittal plane decreased. In this way, the anatomical structure of the foot is preserved, remaining within normal limits, and possible foot pathologies are prevented. In existing literature, it has been stated that up to 25% of dissatisfaction with foot health is due to the limitations of joint angles in MTP, MC, and NC [26]. In particular, one source of dissatisfaction has been reported to be pain due to reduced range of motion in the MTP, gait changes, and heel height restrictions in shoes [27, 28, 30].

The angle of MC in horizontal plane is assigned 6.8° for female, 7.2° for male. On the other hand, the angle of MC in horizontal plane is identified as 6.1° for female and 6.7° for male. It was determined that there was no significant difference between the 2 genders ($p>0.05$). Beeson *et al.*, stated that the angle of MC is 9.7° for male and 9.1

for female [16]. They, however, pointed out that range of age was too big and deformities like hallux rigidus would expand with age. For this reason, the angle of MC is specified as 6.9° for youths who have immature hallux rigidus. Additionally, improvement of hallux valgus accelerate as the angle of MC increases. In another study, being less than 10° for medialin angulation of art.

One of the most important results in our study was to specify the angle of NC joint. Absence of explicit information about NC joint angle in literature makes it important. In horizontal plane, it was measured as 2.1° - 9.4° for females, 3° - 11.4° for males. The angle of NC came up 6.1° for females, 6.5° for males as an average. Since our study was on amputee cadavers, it is needed to examine living individuals in clinical or movement tests to capture the same angle and interpret the relation with MTP and MC joints. Because flattening of the foot under body weight can change the direction of the MTP axis, if the medial arch flattens completely under the applied load, the navicular may fall to the ground. For the navicular to remain in a relative position below the more stable and centrally located tarsometatarsal midfoot joints, the NC joint must be incorporated into the midfoot structure at the right angle.

This research was conducted with the aim of presenting a simple, convenient and reliable method that will provide great convenience to surgeons during foot surgery. It is extremely difficult to determine the joint axes in foot surgery due to the position of the foot arch and bones. With

this research, it is aimed to reveal the axial angles of the joints, which is a practical and applicable method in the clinic.

Consequently, MTP and NC joint affect each other, whereas MC joint has only a negative relation with MTP in sagittal plane. As tibial length increases, the angle between MC in horizontal plane and foot midline decreases while the angle between NC in lateral plane and ground increases. Thus individuals who have long tibial or long foot have normal angles that prevent them from having foot deformities. Although various external deforming forces disrupt medial arch and cause pain and deformities in foot, if the effect of MTP, MC and NC angles on foot anatomy is known, a great deal of foot deformities can be corrected. Therefore foot with risk of deformities such as hallux valgus, hallux varus, hallux rigidus will be able to get detected early and appropriate precautions may be advised. We anticipate these joints will verify anatomical data of our study when they are evaluated as biomechanical in chosen clinical cases.

Limitations

This study was performed without the use of radiological imaging due to our research infrastructure and physical conditions. Not being able to support the results of our study radiologically is the biggest limitation of our study. In addition, the fact that the rotational movements of the amputee feet on the biomechanical system were not examined is another limitation of our research.

References

1. Alexander, P, Lau, L. First metatarsophalangeal arthrodesis. *Oper Tech Orthop* 2008;18:221-225.
2. Laporta DM, Melillo TV, Vincent J, Hetherington D. Preoperative assessment in hallux valgus. *Hallux Valgus Forefoot Surg* 1995;123(2):107-123.
3. Fullmari D, Mishra G. Comparative study of viva voce on formalin embalmed cadaver and virtual cadaver using objective structured viva voce as an assessment tool in formative assessment of first MBBS students. *J Krishna Inst Med Sci Univ* 2022;11(3):30-38.
4. Beeson P. The surgical treatment of hallux limitus/rigidus: a critical review of the literature. *The Foot* 2004;14(1): 6-22.
5. Mason LW, Tanaka H. The first tarsometatarsal joint and its association with hallux valgus. *Bone Joint Res* 2012;1(6): 99-103.
6. Kanatli U, Yetkin H, Bolukbasi S. Evaluation of the transverse metatarsal arch of the foot with gait analysis. *Arch Orthop Trauma Surg* 2003;123(4):148-150.
7. Coughlin MJ. Hallux valgus. *J Bone Joint Surg* 1996;78(4):932-966.
8. Ünal KO. (Uzmanlık Tezi Danışman Ulunay Kanatlı). Birinci metatars başı şeklinin halluks valgus deformitesi ile ilişkisi. Gazi Üniversitesi Tıp Fakültesi Ortopedi ve Travmatoloji Anabilim Dalı. 2008. Ankara.
9. Willegger M, Holinka J, Ristl R, Wanivenhaus AH, Windhager R, Schuh R. Correction power and complications of first tarsometatarsal joint arthrodesis for hallux valgus deformity. *Int Ortho* 2015; 39(3):467-476.
10. Smith SE, Landorf KB, Gilheany MF, Menz H. Development and reliability of an intraoperative first metatarsophalangeal joint cartilage evaluation tool for use in hallux valgus surgery. *J Foot Ankle Surg* 2011;50(1):31-36.
11. Lombardi CM, Silhanek AD, Connolly FG, Dennis LN. The effect of first metatarsophalangeal joint arthrodesis on the first ray and the medial longitudinal arch: A radiographic study. *J Foot Ankle Surg* 2002;41(2):96-103.
12. Roukis TS. Clinical outcomes after isolated periarticular osteotomies of the first metatarsal for hallux rigidus: a systematic review. *J Foot Ankle Surg* 2010; 49(6): 553-560.
13. Roukis, TS. Nonunion after arthrodesis of the first metatarsal-phalangeal joint: a systematic review. *J Foot Ankle Surg* 2011; 50(6):710-713.
14. Olewnik Ł. Is there a relationship between the occurrence of frenular ligaments and the type of fibularis longus tendon insertion? *Ann Anat* 2019; 224:47-53.
15. Olewnik Ł. A proposal for a new classification for the tendon of insertion of tibialis posterior. *Clin Anat* 2019; 32(4):557-565.
16. Beeson P, Phillips C, Corr, WS, Ribbans J. Hallux rigidus: A cross-sectional study to evaluate clinical parameters. *Foot (Edinb)* 2009;19(2): 80-92.
17. Dibbern K, Briggs H, Behrens A, McGettigan L, Carvalho KAM, Mansur NSB, et al. Reliability of coronal plane rotation measurements in the medial column of the foot: a cadaveric study. *J Foot Ankle* 2021;15(3):252-8
18. Nery C, Réssio C, de Azevedo Santa Cruz G, de Oliveira RS, Chertman C. Proximal opening-wedge osteotomy of the first metatarsal for moderate and severe hallux valgus using low profile plates. *Foot Ankle Surg* 2013;19(4):276-282.
19. Horton GA, Park YW, Myerson MS. Role of metatarsus primus elevatus in the pathogenesis of hallux rigidus. *Foot Ankle Int* 2012; 20(12):777-784.
20. Lundeen RO, Rose JM. Sliding oblique osteotomy for the treatment of hallux abducto valgus associated with functional hallux limitus. *J Foot Ankle Surg* 2000;39:161-171.
21. Grande-Del-Arco J, Becerro-de-Bengoa-Vallejo R, Palomo-López P, López-López D, Calvo-Lobo C, Pérez-Boal E, et al. Radiographic analysis on the distortion of the anatomy of first metatarsal head in dorsoplantar projection. *Diagnostics (Basel)* 2020;10(8):552.
22. Xu C, Li M, Wang C, Liu H. Range of motion of the first metatarsophalangeal joint after different capsulorrhaphies: A comparative cadaver study. *J Am Podiat Med Assoc* 2019; 109(4):266-271.
23. Jones CP, Coughlin MJ, Grebing BR, Kennedy MP, Shurnas PS, Viladot R, et al. First metatarsophalangeal joint motion after hallux valgus correction: a cadaver study. *Foot Ankle Int* 2005;26(8): 614-169.
24. Kernozek TW, Sterriker SA. Chevron (Austin) distal metatarsal osteotomy for hallux valgus: comparison of pre- and post-surgical characteristics. *Foot Ankle Int* 2002;23(6): 503-508.

25. Ozkurt B, Aktekin CN, Altay M, Belhan O, Tabak Y. Range of motion of the first metatarsophalangeal joint after chevron procedure reinforced by a modified capsuloperiosteal flap. *Foot Ankle Int* 2008; 29(9): 903-909.
26. Dawson J, Coffey J, Doll H, Lavis G, Sharp RJ, Cooke P, *et al.* Factors associated with satisfaction with bunion surgery in 206 women: A prospective study. *Foot* 2007;17(3): 119-125.
27. Hammel E, Abi Chala ML, Wagner T. Complications of first ray osteotomies: a consecutive series of feet with first metatarsal Scarf osteotomy and first phalanx osteotomy. *Rev Chir Orthop Reparatrice Appar Mot* 2007;97(8):93-97.
28. Kumar N, Aithal AP, Ravindra SS, Bishnu A, Nayak SB, Rao MKG. Morphometric and Histological Analysis of 'Spondylosis Deformans' of Thoracic Region in South-Indian Cadaveric Spines. *J Krishna Inst Med Sci Univ* 2017;6(3): 94-102.
29. Smith BW, Coughlin MJ. The first metatarsocuneiform joint, hypermobility, and hallux valgus: What does it all mean? *Foot and Ankle Surg* 2008;14(9):138-141.
30. Glasoe WM, Nuckley DJ, Ludewig PM. Hallux valgus and the first metatarsal arch segment: a theoretical biomechanical perspective. *Phys Ther* 2010; 90(1):110-120.

***Author for Correspondence:**

Dr. Berin Tuğtağ Demir, Ankara Medipol University, Faculty of Medicine, Department of Anatomy, Ankara, Turkey, Email: berrintugtag@hotmail.com

How to cite this article:

Demir BT, Üzel M. The relationship between metatarsophalangeal, metatarsocuneiform and naviculocuneiform joint angles: An anatomical investigation in an Anatolian population. *J Krishna Inst Med Sci Univ* 2023; 12(1):32-42

Submitted: 29-Sep-2022 Accepted: 10-Dec-2022 Published: 01-Jan-2023